

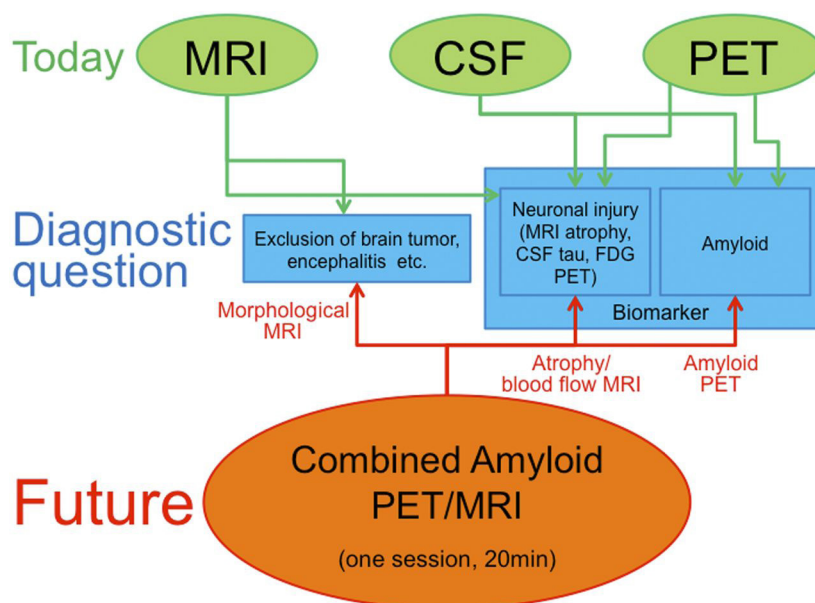
Editorial: Utilization of Hybrid PET/MR in Neuroimaging

Multimodal neuroimaging provides an opportunity to examine different functional, structural, and neurochemical processes simultaneously. This gives us the opportunity to study their interactions in-vivo. The aim of this editorial letter is to give an overview about the applications of hybrid Positron Emission Tomography/Magnetic Resonance Imaging (PET/MR) in multimodal neuroimaging. For many years, researchers and clinicians have tried to combine data obtained with different imaging modalities and scanners, however these efforts have sometimes been hampered by specific limitations. For example, precise co-registration of different modalities has sometimes proven to be challenging (Zaidi, Mawlawi et al., 2007; Gilbert, Scholl et al., 2009; Poole, Bowtell et al., 2009). Moreover, parameters measured in the brain may be subject to rapid changes induced by different cognitive or mood states (e.g. emotion, learning and memory), by brain pathologies (e.g. migraine, vascular disorders, mood disorders) or therapeutic interventions (e.g. antiangiogenic agents). Thus, acquiring different neuroimaging modalities at the same time has been considered a promising alternative to facilitate adjustment for these limitations.

In the early 2000s, hybrid PET/CT scanners have been introduced to allow regional co-registration between

structural and functional imaging in a single scanning procedure. However, the resolution and soft tissue contrast of the CT is clearly inferior compared to MRI to differentiate distinct brain tissue compartments (Delso, Furst et al., 2011; Wehrl, Sauter et al., 2015). Finally, simultaneous PET and MRI acquisition became available for human brain in-vivo imaging (Siemens Healthcare Inc.) (Schlemmer, Pichler et al., 2008). Apart from a better soft-tissue contrast provided by MRI, other advantages of the hybrid PET/MR in comparison to PET/CT are the following: no radiation exposure in MRI, possible motion correction of PET images based on MRI navigator scans, the possibility to perform partial-volume correction of PET data using MRI structural images, and the availability of multiple MRI sequences such as resting-state or task fMRI, diffusion tensor imaging (DTI) or MR-spectroscopy (Catana, Benner et al., 2011; Drzezga, Souvatzoglou et al., 2012; Wehrl, Hossain et al., 2013; Wehrl, Sauter et al., 2015).

Additionally, given the high intra-individual variability of cerebral function and cognitive processing, the simultaneous study of different parameters of brain function or dysfunction in a single examination in the PET/MR scanner can be considered as a promising imaging opportunity. Finally, one-stop acquisition also decreases



NEURSCIENCE

Figure 1. Potential applications of “one-stop shop” MR/PET imaging protocol in diagnosis of Alzheimer disease. This figure was originally published in JNM. Drzezga A. Barthel et al., 2014. Journal of Nuclear Medicine. 2014; 55 (Supplement 2): 47S-55S. © by the Society of Nuclear Medicine and Molecular Imaging, Inc.

the required imaging time for patients and medical staff (one examination instead of two), resulting in higher patient comfort and improved logistics.

On the other hand, it is noteworthy that there have been manifold technical difficulties in the combination of PET and MRI. First, MRI-based attenuation correction (AC) is still a challenge because the CT-based AC methods applied for PET/CT are not available for PET/MR and more complicated MR-based attenuation correction algorithms have to be implemented. Attenuating bone tissue cannot be easily detected using MRI, in contrast to CT (Hofmann, Pichler et al., 2009; Martinez-Moller, Souvatzoglou et al., 2009; Eiber, Martinez-Moller et al., 2011). Recently, a systematic comparison of integrated whole-body PET/MR and conventional PET/CT demonstrated significant region-dependent differences between the scanners potentially due to the inconsistencies in the attenuation-correction procedures (Hitz, Habekost et al., 2014). A recent study indicates that probability-atlas based attenuation correction algorithms may lead to a reduction of these inconsistencies (Izquierdo-Garcia, Hansen et al., 2014).

Studies using hybrid PET/MR to assess physiological and pathophysiological processes in the brain have been very recently reported. For example, our group was able to demonstrate that local brain activity (as reflected by regional glucose metabolism, measured with FDG-PET) in task-related brain areas systematically corresponds to resting-state functional connectivity across associated brain regions in healthy subjects (Riedl, Bienkowska et al., 2014). In neurodegenerative diseases, the PET/MR technique has several benefits. In a clinical setting, MRI can be helpful for differential diagnosis and to exclude non-neurodegenerative etiologies of cognitive impairment. PET using tracers for measuring neuronal metabolism or amyloid-deposition can help in the differential diagnosis of dementia or has great potential to predict the clinical course in pre-dementia stages such as mild cognitive impairment (Hitz, Habekost et al., 2014; Wehrl, Sauter et al., 2015; Drzezga, Barthel et al., 2014) (Figure 1).

PET/MR may also be helpful to unravel pathophysiological mechanisms of neurodegeneration. For instance, a very recent study showed that a decreased intrinsic functional connectivity between hippocampus and precuneus is associated with higher intra-hippocampal metabolism in patients with moderate Alzheimer's disease-dementia. These results support the hippocampus disconnection hypothesis using simultaneous evaluation

of glucose metabolism and intrinsic functional connectivity (Tahmasian, Pasquini et al., 2015).

In summary, simultaneous PET and MRI measurement using a hybrid PET/MR scanner is a promising approach that offers unique opportunities to study the relationship between different parameters of neuronal function, and enables researchers to improve the understanding of the pathogenesis of multifactorial neuropsychiatric disorders like dementia. It may become the neuroimaging method of choice in human brain studies in the future.

Masoud Tahmasian

- Department of Neurology, University Hospital of Cologne, Cologne, Germany;

- Department of Nuclear Medicine, University Hospital of Cologne, Cologne, Germany;

- Sleep Disorders Research Center, Kermanshah University of Medical Sciences (KUMS), Kermanshah, Iran.

masoud.tahmasian@uk-koeln.de

Carsten Eggers

- Neuroimaging and Neuropsychology in Movement Disorders Research Group, Department of Neurology, University Hospital of Cologne, Cologne, Germany.

Valentin Riedl

- Neuroimaging Research Group, Department of Neuroradiology, Klinikum Rechts Der Isar, Technische Universität München, Munich, Germany;

- TUM-NIC Neuroimaging Center, Technische Universität München, Munich, Germany.

Christian Sorg

- Neuroimaging Research Group, Department of Neuroradiology, Klinikum rechts der Isar, Technische Universität München, Munich, Germany;

- TUM-NIC Neuroimaging Center, Technische Universität München, Munich, Germany.

Alexander Drzezga

- Department of Nuclear Medicine, University Hospital of Cologne, Cologne, Germany.

References

- Catana, C., Benner, T., van der Kouwe, A., Byars, L., Hamm, M., Chonde, D. B., Michel, C. J., El Fakhri, G., Schmand, M. and Sorensen, A. G. (2011). "MRI-assisted PET motion correction for neurologic studies in an integrated MR-PET scanner." *Journal of Nuclear Medicine*, 52(1), 154-161.
- Delso, G., Furst, S., Jakoby, B., Ladebeck, R., Ganter, C., Nekolla, S. G., Schwaiger, M., and Ziegler, S. I. (2011). "Performance measurements of the Siemens mMR integrated whole-body PET/MR scanner." *Journal of Nuclear Medicine*, 52(12), 1914-1922.

- Drzezga, A., Souvatzoglou, M., Eiber, M., Beer, A. J., Furst, S., Martinez-Moller, A., Nekolla, S. G., Ziegler, S., Ganter, C., Rummeny, E. J., and Schwaiger, M. (2012). "First clinical experience with integrated whole-body PET/MR: comparison to PET/CT in patients with oncologic diagnoses." *Journal of Nuclear Medicine*, 53(6), 845-855.
- Drzezga, A., Barthel, H., Minoshima, S., and Sabri, O. (2014). "Potential clinical applications of PET/MR imaging in neurodegenerative diseases." *Journal of Nuclear Medicine*, 55(Supplement 2), 47S-55S.
- Eiber, M., Martinez-Moller, A., Souvatzoglou, M., Holzappel, K., Pickhard, A., Loffelbein, D., Santi, I., Rummeny, E. J., Ziegler, S., Schwaiger, M., Nekolla S. G., and Beer, A. J. (2011). "Value of a Dixon-based MR/PET attenuation correction sequence for the localization and evaluation of PET-positive lesions." *European Journal of Nuclear Medicine & Molecular Imaging*, 38(9), 1691-1701.
- Gilbert, K. M., Scholl, T. J., Handler, W. B., Alford J. K., and Chronik, B. A. (2009). "Evaluation of a positron emission tomography (PET)-compatible field-cycled MRI (FCMRI) scanner." *Magnetic Resonance in Medicine*, 62(4), 1017-1025.
- Hitz, S., Habekost, C., Furst, S., Delso, G., Forster, S., Ziegler, S., Nekolla, S. G., Souvatzoglou, M., Beer, A. J., Grimmer, T., Eiber, M., Schwaiger, M., and Drzezga, A. (2014). "Systematic comparison of the performance of integrated whole-body PET/MR imaging to conventional PET/CT for 18F-FDG brain imaging in patients examined for suspected dementia." *Journal of Nuclear Medicine*, 55(6), 923-931.
- Hofmann, M., Pichler, B., Scholkopf B., and Beyer, T. (2009). "Towards quantitative PET/MRI: a review of MR-based attenuation correction techniques." *European Journal of Nuclear Medicine Molecular Imaging*, 36(Suppl 1), S93-104.
- Izquierdo-Garcia, D., Hansen, A. E., Forster, S., Benoit, D., Schachoff, S., Furst, S., Chen, K. T., Chonde, D. B. and Catana, C. (2014). "An SPM 8-based approach for attenuation correction combining segmentation and nonrigid template formation: application to simultaneous PET/MR brain imaging." *Journal of Nuclear Medicine*, 55(11), 1825-1830.
- Martinez-Moller, A., Souvatzoglou, M., Delso, G., Bundschuh, R. A., Ched'hotel, C., Ziegler, S. I., Navab, N., Schwaiger, M., and Nekolla, S. G. (2009). "Tissue classification as a potential approach for attenuation correction in whole-body PET/MRI: evaluation with PET/CT data." *Journal of Nuclear Medicine*, 50(4), 520-526.
- Poole, M., Bowtell, R., Green, D., Pittard, S., Lucas, A., Hawkes, R., and Carpenter, A. (2009). "Split gradient coils for simultaneous PET-MRI." *Magnetic Resonance in Medicine*, 62(5), 1106-1111.
- Riedl, V., Bienkowska, K., Strobel, C., Tahmasian, M., Grimmer, T., Forster, S., Friston, K. J., Sorg, C., and Drzezga A. (2014). "Local activity determines functional connectivity in the resting human brain: A simultaneous FDG-PET/fMRI study." *Journal of Neuroscience*, 34(18), 6260-6266.
- Schlemmer, H. P., Pichler, B. J., Schmand, M., Burbar, Z., Michel, C., Ladebeck, R., Jattke, K., Townsend, D., Nahmias, C., Jacob, P. K., Heiss, W. D. and Claussen C. D. (2008). "Simultaneous MR/PET imaging of the human brain: feasibility study." *Radiology*, 248(3), 1028-1035.
- Tahmasian, M. P. L., Scherr, M., Meng, C., Förster, S., Bratec, S. M., Shi, K., Yakushev, I., Schwaiger, M., Grimmer, T., Diehl-Schmid, J., Riedl, V., Sorg, C., Drzezga, A. (2015). "The lower hippocampus global connectivity, the higher its local metabolism in Alzheimer's disease." *Neurology*, 84(19), 1956-63.
- Wehrl, H. F., Hossain, M., Lankes, K., Liu, C. C., Bezrukov, I., Martirosian, P., Schick, F., Reischl, G., and Pichler, B. J. (2013). "Simultaneous PET-MRI reveals brain function in activated and resting state on metabolic, hemodynamic and multiple temporal scales." *Nature Medicine*, 19(9), 1184-1189.
- Wehrl, H. F., Sauter, A. W., Divine, M. R., and Pichler, B. J. (2015). "Combined PET/MR: A Technology Becomes Mature." *Journal of Nuclear Medicine*, 56(2), 165-168.
- Zaidi, H., Mawlawi, O., and Orton, C. G. (2007). "Point/counterpoint. Simultaneous PET/MR will replace PET/CT as the molecular multimodality imaging platform of choice." *Medical Physics*, 34(5), 1525-1528.