

Unusual Recovery of Aphasia in a Polyglot Iranian Patient after Ischemic Stroke

Masoud Mehrpour*, Mohammad.R Motamed, Mahboubeh Aghaei, Nazanin Jalali, Zahra Ghoreishi

Department of Neurology, Firoozgar Hospital, Tehran University of Medical Sciences, Tehran, Iran.

Article info:

Received: 30 May 2013

First Revision: 29 June 2013

Accepted: 29 August 2013

Key Words:

Aphasia,
Ribot's Law,
Pitres Law.

ABSTRACT

Introduction: Aphasia is a language disorder resulting from a lesion in the cerebral cortex. In this case report, we present a polyglot patient who recovered from aphasia by speaking his newly active learned language

Case Report: A 69 years old male referred with acute onset right hemiparesis and global aphasia. After imaging, he treated with 75 mg r-TPA (0.9 mg/kg). After the fourth day of hospitalization, he could name some objects and some short phrases but interestingly only in French language (although his mother language was Persian).

Discussion: In our patient, recovery was first in the last learned language and his learning memory was recovered earlier than his native languages. As in our case, we can expect to have different recovery theory that means active learning language could be the first part of recovery in aphasia.

1. Introduction

Aphasia is a language disorder resulting from a lesion in the cerebral areas of the dominant hemisphere involved in the elaboration of the expressive and sensory aspects of speech. Lesions of these areas can have a vascular (ischemic or hemorrhagic), traumatic, neoplastic or degenerative basis (Zanini, Angeli, & Tavano, 2011). In spite of the large number of people who are able to speak in one or more language other than the mother language, there are a relatively small number of articles in the available literature that discussed aphasia in bilingual or polyglot subjects (Green, et al., 2010; Green, et al., 2011; Meinzer, Obleser, Flaisch, Eulitz, & Rockstroh, 2007; Tschirren, et al., 2011).

In this case report, we present a polyglot patient who recovered from aphasia at first by speaking his newly active learned language.

2. Case report

A 69 years old male patient who referred to our stroke center, Firoozgar hospital affiliated to Tehran University of Medical Sciences, with acute onset right hemiparesis and global aphasia transferred to emergency department one hour after onset of symptoms. NIHSS was about 18. Brain CT scan showed mild sulcus effacement in left frontoprital lobes (Figure 1). He had no contraindication for thrombolytic therapy. Therefore, he treated with 75 mg r-TPA (0.9 mg/kg) with monitoring of vital signs and checking of any exacerbation in his symptoms. After 24 hours, control brain CT scan showed ischemic stroke in territory of left middle cerebral artery with hemorrhagic transformation (asymptomatic ICH due to thrombolytic therapy) (Figure 2). Hemiparesis and comprehension of the patient got better during next week, and he could understood and obey gradually. After the fourth day of hospitalization, he could name some objects and some short phrases but interestingly only in French language. He could not speak in his mother tongue or his current

* Corresponding Author:

Masoud Mehrpour, MD, MPH

Department of Neurology, Firoozgar Hospital, Tehran University of Medical Sciences, Tehran, Iran.

E-mail: mehrpr@tums.ac.ir

language. He was a polyglot patient who spoke Persian and Turkish since childhood. He learned German when he was 32 years old and lived in Germany for more than 10 years. He started to learn French since one year ago. One week later, his language test showed recovery of French language but no recovery of other languages. His muscle force was about 4/5. He was discharged from hospital and one month later his language tests showed parallel recovery of Turkish and Persian language and he had only anomic aphasia in these two languages.

3. Discussion

Analysis of recovery patterns following aphasia in polyglots may contribute to our understanding of brain-language relationships. Many polyglots with aphasia recover each of their languages in proportion to their premorbid fluency in the language. However, some did not meet. For those cases in which differential recovery patterns is observed, we may ask which language returns first, and why.

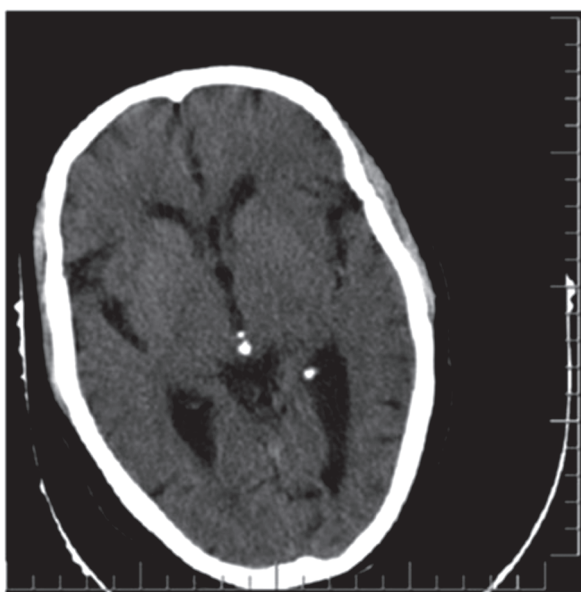
Ribot (Pearce, 2005) supposed that the over learning of items learned early in life rendered these items less susceptible to loss following brain damage and more likely to return first, should such loss occur. The rule of Ribot (Pearce, 2005), then, for polyglot aphasics, is that the first learned language returns first. Pitres (Lorch, 2007) noted that Ribot's (Pearce, 2005) rule did not always hold. He proposed that the language most in use during

the period immediately prior to the onset of aphasia was the one that returned first.

Krapf (Krapf, 1957) observed that often neither "rule" applied, nor they championed a theory of affect. They argued that the social and/or affective environment prior to or following cerebral injury determined which language returned first. Several arguments were proposed and Paradis (Paradis, 2011) categorizes them into: (1) appropriateness of the language to the situation, (2) severity of the lesion, and (3) differential reading knowledge of the languages (e.g. classical Greek). Paradis also identified six recovery patterns of aphasia in polyglot patients:

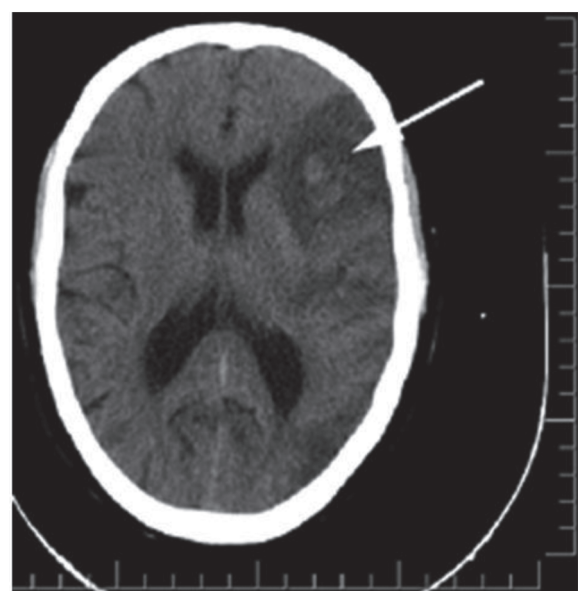
1. Parallel recovery occurs when both languages are impaired and restored at the same rate.
2. Differential recovery occurs when languages recovered differentially relative to their premorbid levels.
3. Selective recovery occurs when one language is not recovered. In blended recovery, patients inappropriately mix their languages. Nearly 30% of the cases show a selective pattern of recovery (the patient did not regain one or more of his languages).

Pitres (Lorch, 2007) reported 2 patients. One patient of recovered French and Spanish, but lost the ability to comprehend Italian. Another patient regained some of his proficiency in French but not in German, English,



NEURSCIENCE

Figure 1. Brain CT scan at admission.



NEURSCIENCE

Figure 2. Control CT Scan (ischemic stroke in territory of left middle cerebral artery with hemorrhagic transformation)

Spanish or Arabic, the all languages he spoke fluently before the injury.

4. Antagonistic type of recovery pattern. One language recovers to some extent first but starts regressing when the other language begins to recover. The antagonistic pattern of recovery is seen to be the least common. By contrast, in selective aphasia, there is aphasia in one language without impairment evidence in the other.

5. Rates of recovery vary. Two languages may eventually be recovered but recovery of the second language may only begin after the first recovered, which is called successive recovery of one language after the other.

6. Less often, there are mixed patterns or mutual interference between the languages seen in the process of recovery.

In our patient, there is a pattern of recovery that may be near to pitres low. Although his first language was neither his current language nor his mother tongue, he had recovery of newly active learned language at first and then the three first learned languages recovered parallel.

Does the age (early or late) of acquiring a language affect the areas of cortex activated whilst using that language, is a matter of debate. The representation of grammatical aspects of languages seems to be different between the two languages if the second language be acquired after the age of 7, with automatic processes and correctness be lower than those of the native language (Pearce, 2005).

In our patient, the recovery was first in the last learned language and his learning memory was recovered earlier than his native languages (Turkish and Persian); this may be compatible with the hypothesis of Krapf (Krapf, 1957).

4. Conclusion

As in our case we can expect to have different recovery theory that means active learning language could be the first part of recovery in aphasia.

References

- Green, D. W., Grogan, A., Crinion, J., Ali, N., Sutton, C., & Price, C. J. (2010). Language control and parallel recovery of language in individuals with aphasia. *Aphasiology*, 24(2), 188-209.
- Green, D. W., Ruffle, L., Grogan, A., Ali, N., Ramsden, S., & Schofield, T., et al. (2011). Parallel recovery in a trilingual speaker: the use of the Bilingual Aphasia Test as a diagnostic complement to the Comprehensive Aphasia Test. *Clin Linguist Phon*, 25(6-7), 449-512.
- Krapf, E. E. (1957). [Not Available]. *Encephale*, 46(5-6), 623-629.
- Lorch, M. (2007). Bilingualism and memory: early 19th century ideas about the significance of polyglot aphasia. *Cortex*, 43(5), 658-666.
- Meinzer, M., Obleser, J., Fleisch, T., Eulitz, C., & Rockstroh, B. (2007). Recovery from aphasia as a function of language therapy in an early bilingual patient demonstrated by fMRI. *Neuropsychologia*, 45(6), 1247-1256.
- Paradis, M. (2011). Principles underlying the Bilingual Aphasia Test (BAT) and its uses. *Clin Linguist Phon*, 25(6-7), 427-443.
- Pearce, J. M. (2005). A note on aphasia in bilingual patients: Pitres' and Ribot's laws. *Eur Neurol*, 54(3), 127-131.
- Tschirren, M., Laganaro, M., Michel, P., Martory, M. D., Di Pietro, M., & Abutalebi, J., et al. (2011). Language and syntactic impairment following stroke in late bilingual aphasics. *Brain Lang*, 119(3), 238-242.
- Zanini, S., Angeli, V., & Tavano, A. (2011). Primary progressive aphasia in a bilingual speaker: a single-case study. *Clin Linguist Phon*, 25(6-7), 553-564.