

## Research Paper

## Assessing the Changes of Cortical Thickness in Alzheimer Disease With MRI Using Freesurfer Software

Nasim Sattari<sup>1</sup> , Fariborz Faeghi<sup>1\*</sup> , Babak Shekarchi<sup>2</sup> , Mohammad Hossein Heidari<sup>3</sup>

1. Department of Radiology, School of Allied Medical Science, Shahid Beheshti University of Medical Sciences, Tehran, Iran.

2. Department of Radiology, School of Medicine, AJA University of Medical Sciences, Tehran, Iran.

3. Department of Basic Sciences, School of Allied Medical Sciences, Shahid Beheshti University of Medical Sciences, Tehran, Iran.



**Citation** Sattari, N., Faeghi, F., Shekarchi, B., Heidari, M. H. (2021). Assessing the Changes of Cortical Thickness in Alzheimer Disease With MRI Using Freesurfer Software. *Basic and Clinical Neuroscience*, 13(2), 185-192. <http://dx.doi.org/10.32598/bcn.2021.1779.1>

<http://dx.doi.org/10.32598/bcn.2021.1779.1>

**Article info:****Received:** 23 Sep 2019**First Revision:** 20 Jun 2020**Accepted:** 25 Aug 2020**Available Online:** 01 Mar 2022**Keywords:**

Alzheimer disease, Cortical thickness, Magnetic resonance imaging (MRI), Freesurfer software

**ABSTRACT**

**Introduction:** In this study, we intend to determine the correlation between the thickness of the cerebral cortex and the severity of the cognitive disorder in Alzheimer disease (AD).

**Methods:** A total of 20 (14 women and 6 men) patients diagnosed with AD with a Mean age of 72.95 years, and 10 (7 women and 3 men) cognitively normal (CN) subjects with a Mean age of 70.50 years were included in the study. Of the AD patient and CN subjects, 70% were female, and 30% were male. All individuals underwent 1.5 T Magnetic resonance imaging (MRI). The MRI scanning protocol included 3D MPRAGE (3D-T1W) sequence. All images were analyzed using Freesurfer v5.3, and then the brain cortical thickness in 7 cortical areas (inferior temporal, middle temporal, superior temporal, parahippocampal, pars triangularis, rostral middle frontal, and superior frontal) was calculated.

**Results:** The analysis of covariance (ANCOVA) was conducted to compare the mean thickness of each region between the patient and the control group. There was a significant difference in the mean cortical thickness in all regions. In all cases, the mean cortical thickness in CN subjects was greater than in AD patients. However, the mean thickness of pars triangularis left hand in CN subjects was not significantly greater than that in AD patients. The receiver operating characteristic system (ROC) was designed to evaluate the predictive power of the patients and the healthy people. We have selected a thousand cut-off points from 1.5 to 3.5 mm for cortical thickness. When the cut-off points were within 2.276878–2.299680 mm in the left hemisphere, Youden's index was maximum. The sensitivity and specificity, in this case, were 80%. Also, when the cut-off points were within the range of 2.263278–2.282278 mm in the right hemisphere, the sensitivity and specificity were 90% and 80%, respectively.

**Conclusion:** This study demonstrates the importance of quantifying the cortical thickness changes in the early diagnosis of AD. In addition, examining the pattern of changes and quantifying the reduction in the thickness of the cortex is a crucial tool for displaying the local and global atrophy of the brain. Also, this pattern can be used as an alternative marker for the diagnosis of dementia. Finally, to the best of our knowledge, our study is the first to report finding on the cortical thickness that would help the clinician have a better differential diagnosis. Also, this study has checked the possibility of early diagnosis of the disease.

**\* Corresponding Author:****Faeghi Fariborz, PhD.****Address:** Department of Radiology, School of Allied Medical Science, Shahid Beheshti University of Medical Sciences, Tehran, Iran.**Tel:** +98 (912) 7171638**E-mail:** [f\\_faeghi@sbmu.ac.ir](mailto:f_faeghi@sbmu.ac.ir)

## Highlights

- The correlation between the thickness of cerebral cortex and the severity of cognitive disorder in Alzheimer's disease was determined.
- The cortical thickness change is an important factor in early diagnosis of Alzheimer's disease.
- The pattern of reduction in the thickness changes is a crucial tool for displaying the local and global atrophy of the brain.

## Plain Language Summary

The neurodegenerative disorder Alzheimer's disease (AD) is a fast-growing epidemic in aging populations worldwide. In 2050, one new case of AD is estimated to increase up to every 33 seconds. So the diagnosis of AD in the early stage considerably decreases the progress of dementia and helps identify a correct treatment approach. The cortical thickness measured by structural neuroimaging has received a significant surrogate biomarker that could provide powerful tools for the early diagnosis of AD. Since the sensitivity and specificity of MRI are higher, it offers essential advantages for identifying brain atrophy patterns. The manual cortical thickness measurement methods are time-consuming and require experienced anatomists compared with automated methods. In this regard, Freesurfer software, which is a freely available program and provides information for quantifying the functional and structural features of the brain, is used. The current study demonstrates examining the pattern of changes and quantifying the reduction in the thickness of the cortex. This can also be used as an alternative marker for the early diagnosis of dementia using cortical thickness measurement that would help the physicians.

### 1. Introduction

**T**he neurodegenerative disorder Alzheimer disease (AD) is a fast-growing epidemic in aging populations worldwide. AD is the most prevalent type of dementia in people over 65 (Korolev, 2014). In 2017, one new case of AD developed every 66 seconds, but by 2050, this time is estimated to increase up to every 33 seconds (Alzheimer's Association Report, 2017). So the diagnosis of AD in the early stage considerably decreases the progress of dementia and helps identify an accurate treatment approach (Mucke, 2009).

Regarding the highly folded pattern of the human brain's cerebral cortex, the characterization of cortical brain structure changes is essential in normal aging and neurodegenerative disorders (Fischl and Dale, 2000). The cortical thickness measured by structural neuroimaging has received a significant surrogate biomarker that could provide powerful tools for the early diagnosis of AD (Querbes et al., 2009).

Gray matter atrophy extending to the medial temporal lobe, parietal lobe, and prefrontal cortices is a morphometric feature of neurodegenerative changes (Ming, Harms, Morris, Beg, & Wang, 2015).

Structural neuroimaging, such as magnetic resonance imaging (MRI) and computerized tomography (CT), offers essential advantages for identifying brain atrophy patterns. MRI has no ionizing radiation and provides higher resolution images of the gray-white matter boundary. MRI also reflects its value in assessing the temporal lobe region because it has no beam hardening artifacts. So, because of all these criteria, the sensitivity and specificity of MRI (80% to 94% sensitivity; 60% to 100% specificity) are higher than CT (63% to 88% sensitivity; 81% specificity) for AD diagnosis (Mueller et al., 2005).

Functional neuroimaging, including brain glucose metabolism and beta-amyloid imaging with single-photon emissions computed tomography (PET) and single-photon emission computed tomography (SPECT), might be better for early detection of dementia because of the higher sensitivity (PET: 94%; SPECT: 70% to 89%) (Mueller et al., 2005; Querbes et al., 2009). Moreover, clinical examination and functional neuroimaging are affected by the cognitive reserve. Therefore, structural neuroimaging has given promising results while being less affected by this factor than other modalities in detecting the early onset of dementia (Querbes et al., 2009).

Today, measuring brain cortical thickness and making surface brain models in MRI are used to distinguish subtle changes in cortical brain structure better. Furthermore, quantitative measurement is sensitive to changes in neurodegenerative diseases (Ming et al., 2015). The manual cortical thickness measurement methods are

time-consuming and require experienced anatomists compared with automated methods (McCarthy, Ramprasad, Thompson, Botti, Coman, & Kates, 2015).

Freesurfer (<https://surfer.nmr.mgh.harvard.edu/>) is a freely available software and can provide information for quantifying the functional and structural features of the brain. Freesurfer is a fully automated corticometry method. Besides, creating surface brain models and the ability to inflate the brain cortex lead to the superior efficiency of this method compared to other software (Fischl, 2012).

Ultimately, assessing cortical brain properties and white matter atrophy has given complementary information about the AD process (Ming et al., 2015). In this study, we emphasized the role of corticometry in the early detection of AD and hypothesized that measurement of cortical thickness would increase the power of differential diagnosis of AD from normal brain aging changes.

## 2. Materials and Methods

A total of 20 (14 women and 6 men) patients with AD with a Mean age of 72.95 years and 10 (7 women and 3 men) healthy individuals as the control group with a Mean age of 70.50 years were included in our study. A neurologist examined all AD patients, and all control subjects had normal MRI and no intracranial pathology. All individuals gave written informed consent and then underwent MRI. The participants from all groups with a history of neurologic or psychiatric disease were excluded from the study.

### MRI examination protocols:

All MRI studies were collected on a 1.5 Tesla GE explorer 360 MRI scanner. The MRI scanning protocol included 3D MPRAGE (3D-T1W) sequence (TR=9.7 ms, TE=3.7 ms, flip angle=12°, NEX=1, Matrix size=256×256, and FOV=25.6). Finally, the expert radiologist checked the quality and probable artifacts of all images.

### Image analysis

All images were analyzed using Freesurfer v5.3, and then the brain cortical thickness in 7 areas of 3 brain regions (inferior temporal, middle temporal, superior temporal, parahippocampus, pars triangularis, rostral middle frontal, superior frontal) was calculated.

At first, DICOM images were converted to .nift format. The images processing steps included skull stripping (removing skull and other structures from brain tissue),

intensity normalization (normalizing the white matter intensity values all around 110), white matter segmentation (the segmentation of white matter from other structures), surface atlas registration (inflation of brain hemisphere and creates a map of brain sulcus), and surface extraction (separating brain hemisphere and creating surface brain model). Finally, thickness measurements were mapped on the inflated surface map.

### Statistical analysis

Statistical analysis of data considering particular characteristics (cortical thickness) was performed in SPSS software v. 23. The analysis of covariance (ANCOVA) was performed based on a vertex-by-vertex procedure to determine if there is a significant difference between regional cortical thickness variations of patients with AD and cognitively normal (CN) subjects; age and gender were adjusted. The homogeneity of gender and age between groups was examined with the Chi-square and independent t test, respectively. The significance was set as  $P < 0.05$ .

Two receiver operating characteristic (ROC) curves were plotted to compare sensitivity versus specificity across a range of cortical thickness values for the ability to predict a dichotomous outcome (AD and CN).

## 3. Results

Ten cognitively normal (CN) subjects and 20 patients diagnosed with AD from Athari Medical Imaging Center were included in the study between December 2016 and May 2017. The Mean age of CN subjects and patients with AD were 70.50 and 72.95 years, respectively. Of the AD patient and CN subjects, 70% were female, and 30% were male (Table 1). The cortical thicknesses (Mean±SE) for each hemisphere and region are presented in Table 2.

A 1-way ANCOVA was conducted to compare the means of each region between the groups after controlling for age and gender as covariates. Levene's test and normality checks were carried out, and the ANCOVA assumptions were met. There was a significant difference in the Mean cortical thickness in regions such as inferior temporal left hand ( $P < 0.001$ ), inferior temporal right hand ( $P < 0.001$ ), middle temporal left hand ( $P = 0.006$ ), middle temporal right hand ( $P = 0.001$ ), superior temporal left hand ( $P = 0.006$ ), superior temporal right hand ( $P < 0.001$ ), parahippocampal left hand ( $P = 0.026$ ), parahippocampal right hand ( $P = 0.049$ ), pars triangularis right hand ( $P = 0.041$ ), rostral middle frontal left hand ( $P = 0.003$ ), rostral middle frontal right hand ( $P = 0.003$ ),

**Table 1.** Demographic statistics

Variables	Mean±SD/No.(%)	
	Cognitively Normal Subjects	Alzheimer Disease Patients
Age (y)	75.50±5.74	72.95±6.87
Gender	Male	3(30)
	Female	7(70)
Total	10	20

NEURSCIENCE

superior frontal left hand ( $P=0.023$ ), and superior frontal right hand ( $P=0.008$ ) between the study groups (CN subjects vs AD patients). In all cases, the Mean cortical thickness in CN subjects was greater than those in the AD patients. However, the Mean thickness of pars triangularis left hand in CN subjects was not significantly greater than that in AD patients (Table 3).

In the current study, sensitivity (“positivity in health”) refers to the proportion of subjects who have the target condition (CN subjects) and give positive test results. Specificity (“negativity in health”) is the proportion of subjects without the target condition who gives negative test results.

We have selected a thousand cut-off points from 1.5 to 3.5, and depending on the cut-off point selected, the sensitivity and specificity of the test changed. When the

cortical thickness of a sample was less than the cut-off, we considered it a negative point (AD patients).

Sensitivity and specificity varied with the cut-off chosen. When the cut-off points were within the 2.276878–2.299680 range in the left hemisphere, Youden’s index was maximum. The sensitivity and specificity, in this case, were 80% (Figure 1A). Also, when the cut-off points were within the range of 2.263278–2.282278 in the right hemisphere, the sensitivity and specificity were 90% and 80%, respectively (Figure 1B).

#### 4. Discussion

Because of the fast-growing rate of dementia, especially AD, all over the world, the promotion of diagnostic approaches at an earlier stage of the disease has an important role (Mucke, 2009). The measurement of brain

**Table 2.** Cortical thickness (Mean±SE) for each hemisphere and region

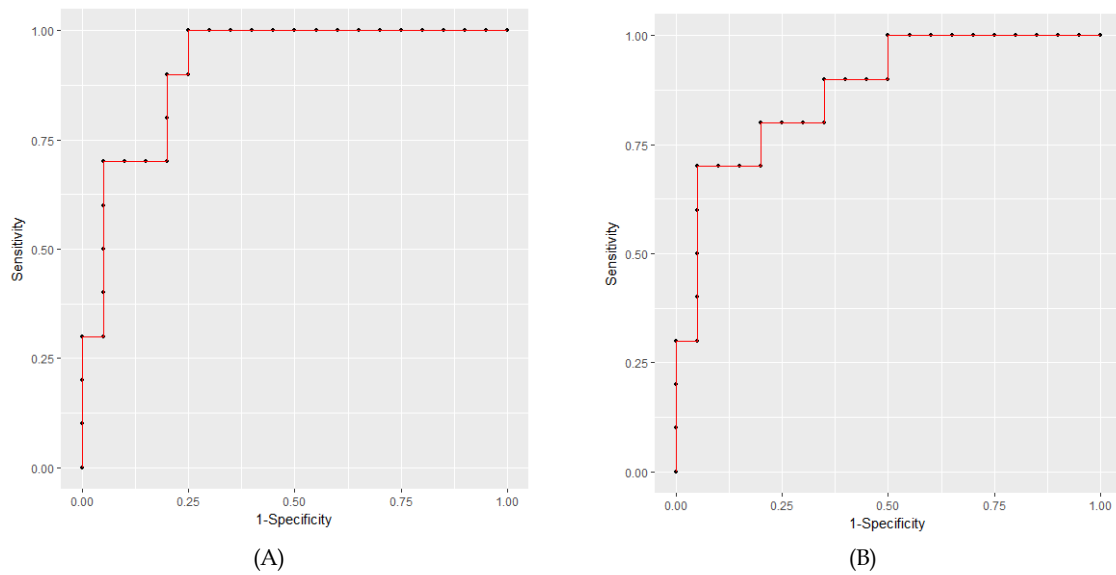
Regions	Mean±SE			
	Cognitively Normal Subjects		Alzheimer Disease Patients	
	Left	Right	Left	Right
Inferior Temporal	2.72±0.13	2.77±0.22	2.35±0.21	2.35±0.23
Middle Temporal	2.52±0.17	2.46±0.18	2.18±0.31	2.22±0.23
Superior Temporal	2.52±0.12	2.57±0.14	2.24±0.25	2.27±0.18
Parahippocampal	2.72±0.56	2.48±0.35	2.27±0.35	2.18±0.32
Pars triangularis	2.06±0.19	2.23±0.26	1.98±0.21	1.95±0.32
Rostral middle frontal	2.13±0.14	2.15±0.22	1.96±0.14	1.94±0.16
Superior frontal	2.37±0.15	2.34±0.15	2.20±0.16	2.15±0.18

NEURSCIENCE

**Table 3.** Result and comparison of mean cortical thickness for each hemisphere and region between groups

Regions	Groups	Mean Difference ( $\mu\text{CN}-\mu\text{AD}$ )	P
Inferior temporal. LH	CN	0.37	<0.001
	AD		
Inferior temporal. RH	CN	0.42	<0.001
	AD		
Middle temporal. LH	CN	0.34	0.006
	AD		
Middle temporal. RH	CN	0.31	0.001
	AD		
Superior temporal. LH	CN	0.28	0.006
	AD		
Superior temporal. RH	CN	0.30	<0.001
	AD		
Parahippocampal. LH	CN	0.45	0.026
	AD		
Parahippocampal. RH	CN	0.30	0.049
	AD		
Pars triangularis. LH	CN	0.08	0.290
	AD		
Pars triangularis. RH	CN	0.28	0.041
	AD		
Rostral middle frontal. LH	CN	0.17	0.003
	AD		
Rostral middle frontal. RH	CN	0.21	0.003
	AD		
Superior frontal. LH	CN	0.17	0.023
	AD		
Superior frontal. RH	CN	0.19	0.008
	AD		

RH, right hemisphere; LH, left hemisphere.



**Figure 1.** Receiver Operating Characteristic (ROC) Curve for Various Cut-off Levels, (A) of Left Hemisphere Regions, (B) of Right Hemisphere Regions

cortical thickness can demonstrate the subtle changes in cortex thinning.

In this study, the main goal was to determine the correlation between the thickness of the cerebral cortex and the severity of the cognitive disorder in AD. So, the amount of cerebral cortex thickness was measured using Freesurfer software.

These changes can be revealed quantitatively by measuring the thickness of the cortex and studying the pattern of its changes. Moreover, it is possible to provide additional information about the process of AD.

The ability to diagnose in early stages of AD increases parallel with the differential diagnostic power between patients with mild Alzheimer and healthy people. So, AD progression can be stopped with the early diagnosis of the disease. Because of the structural nature of the cerebral cortex, which is twisted in several layers, manual methods for determining the thickness of the cortex are problematic, time-consuming, and require a trained anatomist (Fischl & Dale, 2000). That is why automatic Freesurfer software in measuring the thickness of the cortex and quantifying structural properties has the advantage of inflating brain hemispheres and building a surface model (SBM) from the cerebral cortex. Thus, it is possible to get sensitive cortex measurements in mm in neurodegenerative diseases.

Data achieved from Freesurfer software were studied for statistical analysis. The results of our study were

in agreement with the results of studies by Salat et al. (2004), Ridway et al. (2012), and Jing Ming et al. (2015). Reducing the thickness of the cerebral cortex was observed in all studies.

The study results showed that changes in the thickness of the cortex were correlated with the severity of AD. In other words, in all the seven cortical areas studied, the Mean cortical thickness of the brain in Alzheimer patients was significantly lower than that of the control group except for the pars triangularis cortex in the left hemisphere of the brain. The difference between the Mean cortex thickness in healthy subjects and AD patients was very small and not statistically significant in this area.

That is the only difference between our study and others. This slight difference in the thickness of the pars triangularis cortex can be due to the small sample size. To investigate the possibility of early diagnosis of AD, there was no significant difference in the Mean brain cortex in three patients in the control group with the AD patients. In these three people, the thickness of the cortex has been reduced so much, which is close to the thickness of the cortex in people with AD. It can be concluded that this reduction in thickness is due to the normal process of aging. Then, if they had symptoms of AD in clinical trials, they must be considered as a susceptible person to the disease, which must undergo more clinical examination.

The receiver operating characteristic system (ROC) was designed to evaluate the predictive power of the patient and the healthy person. According to the ROC curve, if

the thickness of the left hemisphere cortex is less than 2.27–2.22 mm, with a sensitivity of 80%, we can say that the person has AD. The specificity is also 80%. Sensitivity and specificity were 90% and 80%, respectively, when the average thickness of the cortex was about 2.28–2.26 mm in the right hemisphere of the brain. In most previous studies, the sensitivity and specificity based on the thickness of the cortex for predicting a healthy or AD person have not been calculated. However, our study, in addition to determining the thickness of the cortex in the normal and AD patients, compared them and calculated the sensitivity and specificity of the procedure.

This study has several limitations. The first is the insufficient collaboration of the patients with AD during the imaging and also 3D-T1w images collection, which may affect the software analysis. However, images with motion artifacts were excluded from the study. The second limitation is the software errors. Because Freesurfer is automatic, there may be errors during the analysis, but we did the three-step quality check as far as possible to optimize the software analysis stage. Thirdly, the sample size was small.

According to the study results, it is suggested that future studies be carried out in a wide range of samples to obtain better and more accurate results. Also, considering that this study was performed on 7 cortical areas of the brain, it is recommended that subsequent studies be performed on other cortical areas. In further studies, patients in the mild cognitive impairment (MCI) stage with a high sample volume could be considered. Using three Tesla MRI devices makes it easier to measure a few changes in the thickness of the cerebral cortex, especially in patients with MCI.

## 5. Conclusion

To the best of our knowledge, our study is the first one to report finding on the cortical thickness that would help the clinician have a better differential diagnosis, and also, this study has checked the possibility of early diagnosis of the disease. This study demonstrates the importance of quantifying the cortical thickness changes in the early diagnosis of AD. In addition, examining the pattern of changes and quantifying the reduction in the thickness of the cortex is an important tool for displaying the local and global atrophy of the brain. Also, this pattern can be used as an alternative marker for the diagnosis of dementia (Pini et al., 2016).

## Ethical Considerations

### Compliance with ethical guidelines

All ethical principles are considered in this article. The participants were informed of the purpose of the research and its implementation stages. They were also assured about the confidentiality of their information and were free to leave the study whenever they wished, and if desired, the research results would be available to them. A written consent has been obtained from the subjects. principles of the Helsinki Convention was also observed.

### Funding

This research did not receive any grant from funding agencies in the public, commercial, or non-profit sectors.

### Authors' contributions

All authors equally contributed to preparing this article.

### Conflict of interest

The authors declared no conflict of interest.

## References

- Alzheimer's Association Report. (2017). 2017 Alzheimer's disease facts and figures. *Alzheimer's & Dementia*, 13(4), 325-373. [DOI:10.1016/j.jalz.2017.02.001]
- Fischl, B. (2012). FreeSurfer. *NeuroImage*, 62(2), 774-781. [DOI:10.1016/j.neuroimage.2012.01.021] [PMID] [PMCID]
- Fischl, B., & Dale, A. M. (2000). Measuring the thickness of the human cerebral cortex from magnetic resonance images. *Proceedings of the National Academy of Sciences of the United States of America*, 97(20), 11050-11055. [DOI:10.1073/pnas.200033797] [PMID] [PMCID]
- Korolev, I. O. (2014). Alzheimer's disease: A clinical and basic science review. *Medical Student Research Journal*, 4(Fall):24-33. <https://msrj.chm.msu.edu/fall-2014-24/>
- Mucke L. (2009). Neuroscience: Alzheimer's disease. *Nature*, 461(7266), 895-897. [DOI:10.1038/461895a] [PMID]
- McCarthy, C. S., Ramprashad, A., Thompson, C., Botti, J. A., Coman, I. L., & Kates, W. R. (2015). A comparison of FreeSurfer-generated data with and without manual intervention. *Frontiers in Neuroscience*, 9, 379. [DOI:10.3389/fnins.2015.00379]
- Ming, J., Harms, M. P., Morris, J. C., Beg, M. F., & Wang, L. (2015). Integrated cortical structural marker for Alzheimer's disease. *Neurobiology of aging*, 36 (Suppl 1), S53-S59. [DOI:10.1016/j.neurobiolaging.2014.03.042] [PMID] [PMCID]

- Mueller, S. G., Weiner, M. W., Thal, L. J., Petersen, R. C., Jack, C. R., Jagust, W., et al. (2005). Ways toward an early diagnosis in Alzheimer's disease: The Alzheimer's Disease Neuroimaging Initiative (ADNI). *Alzheimer's & Dementia: The Journal of the Alzheimer's Association*, 1(1), 55-66. [DOI:10.1016/j.jalz.2005.06.003] [PMID] [PMCID]
- Pini, L., Pievani, M., Bocchetta, M., Altomare, D., Bosco, P., Cavedo, E., et al. (2016). Brain atrophy in Alzheimer's Disease and aging. *Ageing Research Reviews*, 30, 25-48. [DOI:10.1016/j.arr.2016.01.002] [PMID]
- Querbes, O., Aubry, F., Pariente, J., Lotterie, J. A., Démonet, J. F., Duret, V., et al. (2009). Early diagnosis of Alzheimer's disease using cortical thickness: Impact of cognitive reserve. *Brain : A Journal of Neurology*, 132(Pt 8), 2036-2047. [DOI:10.1093/brain/awp105] [PMID] [PMCID]
- Ridgway, G. R., Lehmann, M., Barnes, J., Rohrer, J. D., Warren, J. D., Crutch, S. J., et al. (2012). Early-onset Alzheimer disease clinical variants: Multivariate analyses of cortical thickness. *Neurology*, 79(1), 80-84. [PMID]
- Salat, D. H., Buckner, R. L., Snyder, A. Z., Greve, D. N., Desikan, R. S., Busa, E., et al. (2004). Thinning of the cerebral cortex in aging. *Cerebral Cortex (New York, N.Y. : 1991)*, 14(7), 721-730. [PMID]