

# Neuroprotective Effects of Epigallocatechin-3-Gallate in an Experimental Model of Alzheimer's Disease in Rat: A Histological Study

Homa Rasouli<sup>1\*</sup>, Mohammad Taghi Joghataie<sup>1</sup>, Mehrdad Roghani<sup>2</sup>, Maliheh Nobakht<sup>1</sup>

1. Department of Anatomy, School of Medicine, Iran University of Medical Sciences, Tehran, Iran.

2. Department of Physiology, School of Medicine, Shahed University, Tehran, Iran.

Article info:

Received: 10 August 2009

First Revision: 20 September 2009

Accepted: 30 September 2009

## ABSTRACT

**Introduction:** Neurodegeneration change is one of the hallmark symptoms of which Alzheimer's disease (AD) can be modeled by  $\beta$ -amyloid injection into specific regions of brain. (-)-Epigallocatechin-3-gallate (EGCG) is a potent antioxidant agent that its role against oxidative stress and inflammation has been shown in prior studies. In the present study, we have wanted to determine whether EGCG administration protects against  $\beta$ -amyloid induced cell damages in rats.

**Methods:** Animals (male Wistar rats) divided into four groups: sham operated (SH), EGCG-pretreated sham operated (SH + EGCG), untreated lesion (L), and EGCG-pretreated lesion (L + EGCG). Animals in L, L + EGCG, and SH + EGCG groups received sterile saline or saline plus EGCG (10 mg/kg) intraperitoneally one day pre-surgery and every other day for three weeks. The lesion was induced one day after EGCG treatment by injection of water or water containing 2 nmol/ $\mu$ l of  $\beta$ -amyloid (1-40) into the hippocampal fissure. We evaluated the morphological changes of hippocampus specially CA3 region by nissl staining after three weeks of surgery.

**Results:** We found that  $\beta$ -amyloid (1-40) injection into hippocampus causes cell death of CA3 region in L group in comparison with SH group which also occurs in the Alzheimer's disease. On the other hand, treatment with EGCG can improve the validity of these cells in hippocampus.

**Discussion:** We concluded that EGCG could be effective in protection against pathogenesis of Alzheimer's disease.

## Key Words:

Alzheimer's disease,  
Hippocampus,  
Epigallocatechin gallate;  
Neurodegeneration,  
CA3

## 1. Introduction

**A**lzheimer's disease (AD) is the most common cause of dementia (1-2). The prevalence and incidence of AD have been shown to increase with age. The typical neuropathological changes in this degenerative disease were first described nearly one hundred years ago (3) by Alois Alzheimer in 1906 (4-5). The two major microscopically lesions are amy-

loid plaques and neurofibrillary tangles (NFT), which are found significantly more in AD than normal aging (6-7). Among several pathogenic mechanisms for AD, it seems inflammation, genetic factors (8), and oxidative stress (5) has more important roles. In addition,  $\beta$ -amyloid has been shown to induce oxidative stress as well (7) through inducing the formation of unusually high concentration of oxygen and nitrogen-reactive species and a depletion of endogenous antioxidants that play a central role in damaging and killing neurons (5).

### \* Corresponding Author:

Dr. Homa Rassouli,

Department of Anatomy, School of Medicine, Iran University of Medical Sciences, Tehran

E-mail:

Neuronal degeneration and death in the neocortex and hippocampus are probably the causes of the impressive behavioral and functional deficits of patients with AD (9).

The hippocampal formation is thought to be the site of initiation of Alzheimer's pathology, and is widely damaged in this disease (10). Although the search for a treatment for AD has not been successful (11), antioxidants showed beneficial effects in patients with AD, slowing the progression of disease (5). In this respect, green tea contains many polyphenolic antioxidants and (-)-epigallocatechin-3-gallate (EGCG) is the most powerful antioxidant responsible for anti-inflammation, neuroprotection and cancer chemoprevention (12), anti-angiogenic properties (13) and is a free radical scavenging substance (14-15).

Therefore, the present study was conducted to evaluate the histological effect of EGCG on neuronal protection in an experimental model of Alzheimer's disease in rat.

## 2. Methods

### 2.1. Materials

$\beta$ -amyloid protein fragment (1-40) and (-)-Epigallocatechin-3-gallate (EGCG) were purchased from Sigma Co. (USA). The  $\beta$ -amyloid (1-40) was dissolved in deionized water at a concentration of 2 nmol/ $\mu$ l and then liquated and stored at  $-70^{\circ}\text{C}$  before use. EGCG was dissolved in sterile normal saline immediately prior to use at final concentration of 5 mg/ml.

### 2.2. Animals

In this study, male Wistar rats weighing 240-300 g (Pasteur's institute, Tehran) were used. These animals were housed in laboratory cages and maintained on a 12-h light-dark cycle with free access to food and water throughout the study.

### 2.3. Experimental Procedure

The animals ( $n=16$ ) were randomly divided into four groups, i.e., sham-operated (SH), EGCG-pretreated sham-operated (SH + EGCG), lesion (L), and EGCG-pretreated lesion (L + EGCG). In this respect, SH group received normal saline intraperitoneally and 4  $\mu$ l of water into the hippocampal fissure. In addition, SH + EGCG group also received 10 mg/kg of EGCG one day pre-surgery and continued every other day for 3 weeks. L group received normal saline intraperitoneally and intrahippocampal injection of  $\beta$ -amyloid protein fragments (1-40) and water as the vehicle. Meanwhile, L + EGCG group also received EGCG like SH + EGCG group.

Animals were anesthetized by intraperitoneal application of xylazine (20 mg/kg) and ketamine (100 mg/kg) and placed in a stereotaxic apparatus (Stoelting Co.). Unilateral lesion of the hippocampus (left side) was made by an injection of 4  $\mu$ l of water or water containing  $\beta$ -amyloid protein fragment (1-40) delivered by a 5  $\mu$ l Hamilton syringe at the level of the hippocampal fissure at the stereotaxic coordinates used on the Paxinos and Watson atlas (1986): antero-posterior, -3.8 mm; lateral, 2 mm from bregma, and -3.5 mm ventral from skull surface with the incisor bar set at -3.3 mm. Injection was made during a 5-min period and then remained in place for 5 min before being slowly withdrawn. During the surgery, we tried to keep the animals' body temperature by using a warm cloth on it. After finishing the surgery, we put the animals singly in the warm place and single cage to awake and after inhalation of their scar they were placed in cages with 2-3 animals. Then, we perfused them after three weeks of treatment through the ascending aorta and with 4% buffered paraformaldehyde, following the normal saline passing the vessels.

We have studied the paraffin slides coronal sections of the brain with 10- $\mu$ m thickness, which were stained by Nissl (Cresyl violet acetate) staining. In this project, we evaluated the number of CA3 pyramidal cells, density of glial cells, and density of microvessels in CA3 region of hippocampus (of left side) in the two coronal sections related to the bregma: -3.6 and -4.1. Then we consider the mean of each measurement in three slides for each of both coronal sections.

### 2.4. Number of CA3 Pyramidal Cells

We counted these cells due to the mediolateral direction in the medial one third of CA3 region that is enclosed by two blades of dentate gyrus. We consider only the neurons with clear nucleus and sharp nucleolus.

### 2.5. Density of Neuroglial Cells in CA3 Region

For this purpose, we selected the lateral one third of the medial part of CA3 region and counted the glial cells in the surface equal to 40  $\mu\text{m}^2$ . This measurement in each sample, was done in two coronal sections (-3.6 and -4.1 from bregma) and in three slides for each section. Then the mean of these measurements was graded in 20s numbers (from 10s-90s) and scaled from 1 to 4.

### 2.6. Density of Microvessels in CA3 Region

In this study, we selected the lateral one third of the medial part of CA3 region too and counted the microvessels in the surface equal to 160  $\mu\text{m}^2$ . This measurement in each sample, was done in two coronal sections (-3.6 and -4.1 from bregma) and in three slides for each

section. Then the mean of these measurements was analyzed. We considered only the vessels which have diameter below 10  $\mu\text{m}$ .

### 2.7. Statistical Analysis

All results were expressed as mean  $\pm$  SEM. The statistical test of Kruskal- wallis was used for comparison between all groups and Mann-whitney Test for each two groups. In all calculations, a difference at  $p < 0.05$  was regarded as significant.

## 3. Results

All experimental animals well tolerated surgical operation with no mortality until the end of the study. Since differences for the results of behavioral tests were not statistically significant for SH and SH + EGCG groups, therefore, the results of these two groups are presented as SH group only.

### 3.1. General features

There was seen a various shape of cell damages and increase of glial cells in the left side (that we injected beta amyloid or water) of slides in all groups as compared to the right side (intact side) due to the direction of injection site specially in the CA1 and outer blade of dentate gyrus, as it has shown in Figure 1. In addition, we could find some aggregation materials in the slides of L group.

### 3.2. Number of CA3 Pyramidal Cells

As it is shown in Figures 2, 3, and 4, we found that there is a significant decrease in the number of CA3 cells in L group as compared to SH and L+EGCG groups in both sections.

### 3.3. Number of CA3 Pyramidal cells in the section of -3.6 from bregma

As Figure 3 shows, the mean number of CA3 neurons in this section for SH, L, and L + EGCG groups were 126.7, 56.1 and 116.7 respectively. However, mean of cell numbers between all groups showed a significant difference ( $p < 0.005$ ). There was also a significant decrease in this parameter in L group in comparison with SH group ( $p < 0.005$ ) and there was a difference between groups (L and L + EGCG groups) with a significant difference ( $p < 0.01$ ). Furthermore, there was no significant difference between SH and L + EGCG groups. On the other hand, mean of cell numbers in L group shows almost 56 percent in comparison with SH group and 52 percent with L+EGCG group.

### 3.4. Number of CA3 pyramidal Cells in the Section of -4.1 from Bregma

The mean number of CA3 neurons in this section for SH, L, and L + EGCG groups were 119.7, 58, and 107.7 respectively. However, as Figure 4 shows, mean of cell numbers between all groups showed a significant difference ( $p < 0.01$ ). There was also a significant decrease in this parameter in L group in comparison with SH group ( $p < 0.01$ ) and there was a difference between groups (L and L + EGCG groups) with a significant difference ( $p < 0.01$ ). Furthermore, there was no significant difference between SH and L + EGCG groups. On the other hand, mean of CA3 cells number in L group shows almost 52 percent in comparison with SH group and 45 percent with L+EGCG group.

### 3.5. Graded Density of Neuroglial Cells in CA3 Region

As it is shown in Table 1, we found that there is a significant difference between all groups in the mean of graded density of glial cells only in the section of -4.1 from bregma ( $p < 0.05$ ). Also there was a significant increase in the mean of graded density of glial cells in L group as compared to the SH group ( $p < 0.05$ ). Although, there was considerable decrease in the mean of graded density of glial cells in L+EGCG group as compared to L group, but there was no significant difference between two groups. Furthermore, there was no significant difference between SH and L + EGCG groups. On the other hand, mean of graded density of glial cells in L group is almost 59 percent in comparison with SH group and 52 percent with L+EGCG

group. Because, we have seen some differences between results in two sections, we evaluated the mean of this parameter in both sections for each animal again. However,

the mean number of this parameter in SH, L, and L + EGCG groups were 1.4, 2.3 and 1.3 respectively. As Figure 5 shows, there was no significant difference between all groups. On the other hand, the mean of graded density of glial cells in L group shows almost 46 percent increase in comparison with L+EGCG group.

### 3.6. Density of Microvessels in CA3 Region

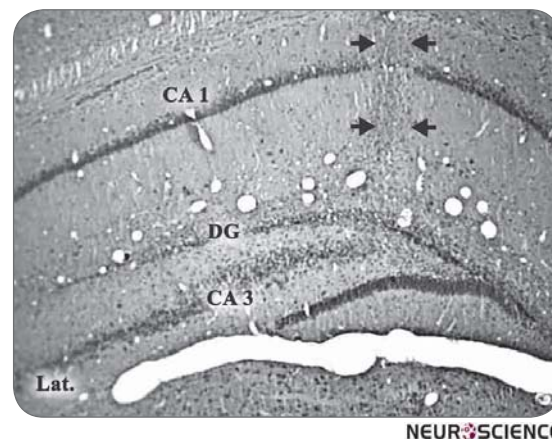
As it is shown in Table 1, we found that although there is considerable decrease between both groups of L and L+EGCG comparison with SH group in the mean of density of microvessels in the section of -3.6

from bregma, there is only a significant difference between all groups for the mean of density of microvessels in the section of -4.1 from bregma ( $p < 0.05$ ). Also there was not a complete significant decrease in the mean of density of microvessels in L group as compared to the SH group ( $p = 0.05$ ). There was a significant decrease in the mean of density of microvessels in L+EGCG group as compared to SH group, but there was no significant difference between two main groups (L and L+EGCG).

Because we have seen some differences between results in two sections, we evaluated the mean of this parameter in both sections for each animal again. However, the mean number of this parameter in SH, L, and L + EGCG groups were 23.9, 15.8 and 15.2 respectively. As Figure 6 shows, there was a significant difference between all groups ( $p < 0.05$ ). There was a significant difference not only between SH group and L group ( $p < 0.05$ ) but also between SH group and L+EGCG group ( $P < 0.05$ ). On the other hand, the mean of density of microvessels in CA3 region in SH group shows almost 34 percent increase in comparison with L group and 36 percent in comparison with L+EGCG group.

#### 4. Discussion

The AD model as used in this research study showed that intrahippocampal injection of 4  $\mu$ l of  $\beta$ -amyloid (2 nmol/ $\mu$ l) could induce toxic and neurodegenerative changes in CA3 region of hippocampus, which were



**Figure 1.** The site of A $\beta$  injection in hippocampus in lesion group. CA1 & CA3 = fields of hippocampus, dg= dentate gyrus. Arrow heads show the site of injection. X100.

**Table 1.** Density of glial cells and microvessels in CA3 region of hippocampus

Groups	Measurement	SH	L	L + EGCG
		SEM $\pm$ mean	SEM $\pm$ mean	SEM $\pm$ mean
Graded Density of Glial Cells in CA3 (-3.6)		1.4 $\pm$ 0.2	2.3 $\pm$ 0.6	1.3 $\pm$ 0.3
Graded Density of Glial Cells in CA3 (-4.1)		1.1 $\pm$ 0.1	*2.7 $\pm$ 0.5	1.3 $\pm$ 0.3
Density of Microvessels in CA3 (-3.6) (Number)		23.8 $\pm$ 4.8	15.22 $\pm$ 1.6	15.17 $\pm$ 1
Density of Microvessels in CA3 (-4.1) (Number)		24 $\pm$ 3.4	16.3 $\pm$ 2.2	*15.3 $\pm$ 1

NEURSCIENCE

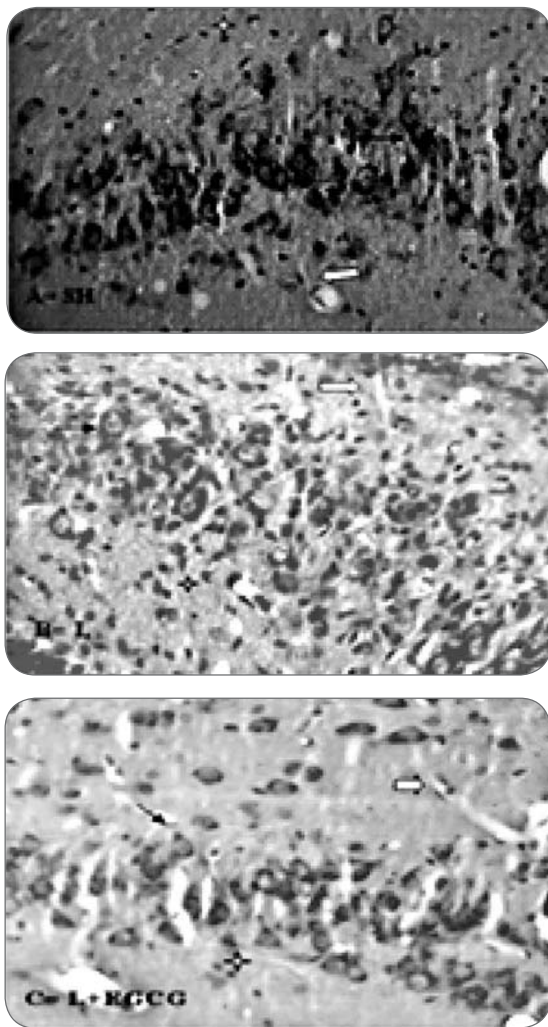
evaluated by measuring the number of CA3 pyramidal cells, graded density of glial cells and density of microvessels in the same region. Measuring the number of CA3 pyramidal cells showed that L group had a decrease in mean number comparison with SH group. In addition, density of microvessels in L group showed decrease in comparison with SH group. Although, it has been shown that there are considerable increase in the graded density of glial cells in L group compared to other both groups, but there was not any significant change in this parameter between groups, may be due to the dose or duration of EGCG pretreatment.

In Alzheimer's disease (AD), the free radicals that have been incriminated as causing neuronal degeneration are believed to be generated by beta-amyloid and/or activated microglia. Neuronal damage may be attributed to oxidative processes initiated by amyloid-derived

free radicals species (16). Actually  $\beta$ -amyloid neurotoxicity has been reported to be mediated by free radicals and attenuated by antioxidants and free radical scavengers (17). In addition,  $\beta$ -amyloid injection into hippocampus showed learning impairment and hippocampal neurodegeneration (18). In present study, also it has shown that intraperitoneal injection of 10 mg/kg of EGCG administered a day before surgery and continued every other day for three weeks may prevent the neurodegenerative changes of CA3 cells of hippocampus against the beta amyloid induce degenerative changes in the animal models of AD.

The mechanism of action of EGCG is still unclear (19). EGCG have phenol rings that act as electron traps to scavenge peroxy radicals, superoxide anions, and hydroxyl radicals and prevent oxidation of iron. Therefore, it seems that in addition to the reduction of iNOS expression, these compounds may block peroxynitrite and nitrite production

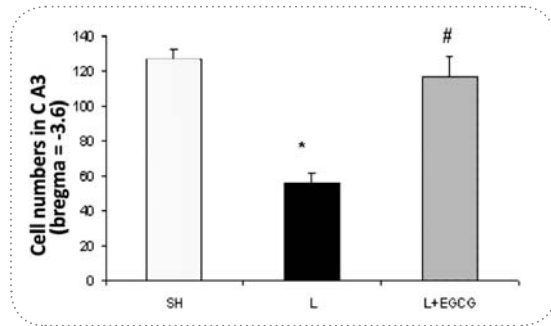




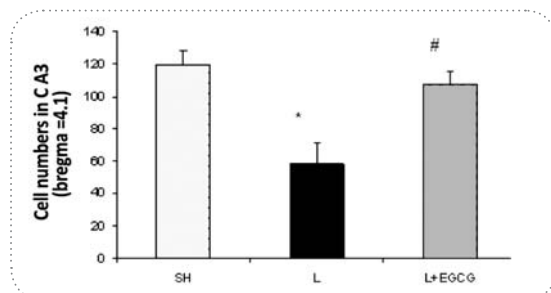
**Figure 2.** A,B and C show CA3 region of hippocampus in groups of study. Stars show the glial cells. White arrows show the microvessels and black arrows show the pyramidal CA3 cells. Notice to the decreased CA3 neurons in L group in part B. X 400.

through inhibition of oxidative reactions (20). In addition, EGCG may act as an antioxidant and anti-inflammatory agent (12) against  $\beta$ -amyloid aggregation in hippocampus and in this way EGCG may have a neuroprotective effect. Actually,  $\beta$ -amyloid neurotoxicity has been reported to be mediated by free radicals and attenuated by antioxidants and free radical scavengers (17). EGCG has been shown to prevent  $A\beta$  induced hippocampal neuronal cell death in cultured hippocampal neurons through its antioxidant property (21). Intraperitoneal injection of EGCG in mutant APP (Amyloid Precursor Protein) mice daily for 2 months indicated the reduced total  $A\beta$  levels (22).

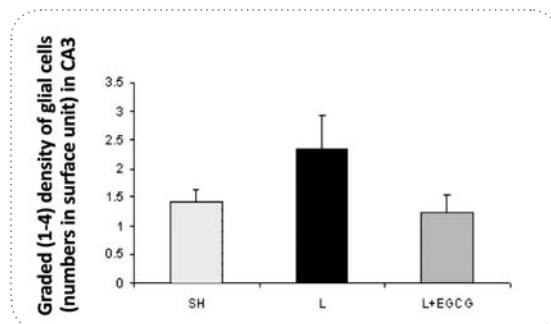
In conclusion, the present results show two important issues. First, unilateral intrahippocampal injection of 2 nmol/ $\mu$ l  $\beta$ A (1-40) induce neurodegenerative changes in



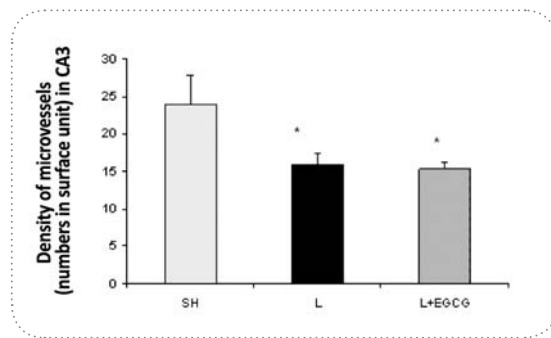
**Figure 3.** The number of CA3 neurons in -3.6 coronal section from bregma. \* $P < 0.005$  as compared to the SH group and # $P < 0.01$  in compared to the L group.



**Figure 4.** The number of CA3 neurons in -4.1 coronal section from bregma. \* $P < 0.01$  as compared to the SH group and # $P < 0.01$  in compared to the L group.



**Figure 5.** Graded density of glial cells in CA3 region of hippocampus. There was no significant differences study



**Figure 6.** Density of microvessels in CA3 region of hippocampus. \* $P < 0.05$  in compared to the SH group.

CA3 region in hippocampus in rats and second, intraperitoneal injection of 10 mg/kg EGCG one day prior surgery and continued every other day for three weeks may prevent the neurodegenerative changes significantly in the animal models of AD. However EGCG couldn't prevent from decrease of microvessels. We believe that further histological studies will be required to find the real therapeutic role and most effective dose of EGCG.

In summary, we conclude that EGCG could be effective in protection against pathogenesis of Alzheimer's disease.

### Acknowledgement

We thank a lot from the helps of Dr. Tourandokht Baluchnejadmojarad; Tayebah Rastegar, and Farzaneh Mohammadzadeh. This work was supported by a grant from Iran University of Medical Sciences (IUMS).

### References

- Oskar H, Henrik Z, Peder B, Elisabet L, Kaj B, and Lennart M. Association between CSF biomarkers and incipient Alzheimer's disease in patients with mild cognitive impairment: a follow-up study. *Lancet Neurol* 2006; 5: 228-34.
- Tiraboschi P, Hansen LA, Thal LJ, and Corey-bloom J. The importance of neuritic plaques and tangles to the development and evolution of AD. *Neurology* 2004; 62: 1984-1989.
- Suzanne H, Michael LS. Alzheimer's Disease: A Review for the Ophthalmologist. *Surv Ophthalmol* 2001; 45(6): 516-524.
- Parihar MS, Taruna H. Alzheimer's disease pathogenesis and therapeutic interventions. *J Clin Neurosci* 2003; 11(5): 456-467.
- Ricardo BM, Juan, PM, Luis B. The Molecular Bases of Alzheimer's Disease and Other Neurodegenerative Disorders. *Arch Med Res* 2001; 32: 367-381.
- Vincent WD. Pharmacologic Treatment of Alzheimer's Disease: An Update. *Am. Fam. Physician* 2003; 68(7): 1365-1372.
- William AB, Susan AF. Antiaging methods and medicines for the memory. *lin Geriatr Med* 2004; 20: 317-328.
- Anthony HVJ, William WL. Alzheimer's disease and angiogenesis. *The Lancet* 2003; 361: 605-08.
- Miguel-Hidalgo JJ, Alvarez XA, Cacabelos R, Quack G. Neuroprotection by memantine against neurodegeneration induced by  $\beta$ -amyloid(1-40). *Brain Res* 2002; 958: 210-221.
- Mcdonald MP, Overmier JB. Present Imperfect: A Critical Review of Animal Models of the Mnemonic Impairments in Alzheimer's Disease. *Neuroscience and Biobehavioral Reviews* 1998; 22 (1): 99-120.
- Mcdonald MP, Overmier JB. Present Imperfect: A Critical Review of Animal Models of Mnemonic Impairments in Alzheimer's Disease. *Neurosci Biobehav Rev* 1998; 22(1): 99-12.
- Ewa S-J, Kangjing Z, Jerzy J. Inhibition of lipoxygenase by (-)-epigallocatechin gallate: X-ray analysis at 2.1 Å reveals degradation of EGCG and shows soybean LOX-3 complex with EGC instead. *Int J Mol Med* 2003; 12:415-422.
- Francesca T, Nicoletta F, Silvio DF, Adriana A. Angioprevention: angiogenesis is a common and key target for cancer chemopreventive agents. *Faceb J* 2002; 16: 2-14.
- Rolf B, Philipp AW, Schlenzka L, Mall JW, Beissenhirtz M, Lisdat F. Epigallocatechin Gallate can Significantly Decrease Free Oxygen Radicals in the Reperfusion Injury in Vivo. *Transplant Proc* 2003; 35: 3116-3120.
- Song XZ, Bi ZG, Xu AE. Green tea polyphenol epigallocatechin-3-gallate inhibits the expression of nitric oxide synthase and generation of nitric oxide induced by ultraviolet B in HaCaT cells. *Chin Med J (Engl.)* 2006; 119(4): 282-7.
- Aksenova MV, Aksenov MY, Mactutus CF, Booze RM. Cell Culture Models of Oxidative Stress and Injury in the Central Nervous System. *Current Neurovascular Research* 2005; 2: 73-89.
- Levites Y, Amit T, Mandel S, Toudim MB. Neuroprotection and neurorescue against A $\beta$  toxicity and PKC-dependent release of nonamyloidogenic soluble precursor protein by green tea polyphenol (-)-epigallocatechin-3-gallate. *FASEB J* 2003; 17(8): 952-4.
- Alvarez XA, Miguel-Hidalgo JJ, Lagares R, Franco A, Fernandez-Novoa L, Beyer K, Lao JI, Vecino B, Cacabelos R, Diaz J, Sempere JM. Protective Effects of Anapsos in Rats with Hippocampal Neurodegeneration. *Eur Neuropsychopharmacol* 1996; 6: 75.
- Basini G, Bianco F, Grasselli F. Epigallocatechin-3-gallate from green tea negatively affects swine granulose cell function. *Domes Anim Endocrin* 2005; 28: 243-256.
- Kim SY, Ahn BH, Kim J, Bae YS, Ywak, JY, Min G, Kwon TK, Chang JS, Lee YH, Yoon SH, Min DS. Phospholipase C, protein kinase C, Ca<sup>2+</sup>/calmodulin-dependent protein kinase II, and redox state are involved in epigallocatechin gallate-induced phospholipase D activation in human astrogloma cells. *Eur J Biochem* 2004; 271: 3470-3480.
- Young-Taeg C, Chul-Ho J, Seong-Ryong L, Jae-Hoon B, Won-Ki B, Min-Ho S, Jonghan P, Chan-Woo P, Seong-II S. The green tea polyphenol (-)-epigallocatechin gallate attenuates  $\beta$ -amyloid-induced neurotoxicity in cultured hippocampal neurons. *Life Sci* 2001; 70: 603-614.
- Kavon RZ, Doug S, Nan S, Takashi M, Huayan H, Deborah J, Jared E, Kirk T, Jin Z, David M, John H, Terrence T, Jun T. Green Tea Epigallocatechin-3-Gallate (EGCG) Modulates Amyloid Precursor Protein Cleavage and Reduces Cerebral Amyloidosis in Alzheimer Transgenic Mice. *J Neurosci* 2005; 25: 8807-8814.