

Mercuric Chloride Induced Cell Death in Spinal Cord of Embryo in Rat

Tayebeh Rastegar¹, Maliheh Nobakht¹, Mehdi Mehdizadeh², Ali Shahbazi³

1. Department of Anatomy, Iran University of Medical Sciences, Tehran, Iran

2. Cellular and Molecular Research Center, Department of Anatomy, Iran University of Medical Sciences, Tehran, Iran

3. Physiology Research center, Physiology Department, Iran University of Medical Sciences, Tehran, Iran

Article info:

Received: 8 May 2010

First Revision: 15 June 2010

Accepted: 2 June 2010

Key Words:

Mercuric Chloride,
Prenatal Period,
Spinal Cord

ABSTRACT

Introduction: Because of more exposure to mercury compounds, the prenatal and postnatal neurotoxic effects of mercury compounds have gained more attention in last decade. The aim of this study was to investigate the effects of mercuric chloride intoxication on spinal cord development during prenatal period.

Methods: 36 adult Sprague-dawley rats after observing vaginal mating plaque (zero day of gestation) were divided into six groups: three control groups that received normal saline solution and three experimental groups that injected with mercuric chloride, 2mg/kg/IP, in 8th, 9th and 10th days of gestation. Then, embryos were removed from uterus in 15th day and spinal cord of embryos was studied by histological techniques.

Results: Microscopic study of spinal cord showed that cell death, mitosis division, and extracellular spaces were increased and cells accumulation were decreased in experimental groups. Diameter of ventricular zone was increased and diameter of mantle and marginal zones were decreased.

Discussion: The present study showed that mercuric chloride intoxication in prenatal period can induce cell death and results in neural tube deficits in prenatal rats.

1. Introduction

P revalence of mercury intoxication by food and environmental sources has risen globally in the world. Pollution of soil and water by natural phenomenon such as volcanoes and industrial activities, pollution of marine food resources by mercury in the water, preservative compounds of vaccines and even amalgam filling of teethes are possible causes of mercury intoxication (Clarkson, 1997; Diez, 2009). Mercury has three forms in the environment, elemental mercuric (Hg⁰) or mercuric vapour that is liquid at room temperature with high vapour pressure, mercuric chloride, and organic methyl mercury or MeHg (Clarkson, 1997; Diez, 2009). Mer-

curic chloride (HgCl₂) is a white, crystalline, heavy and poisonous powder that is used in antiseptics, antifungal and anti-parasite materials (Reynolds, Parfitt, & Parson, 1993). It also has been used in composition of beauty creams, laxative drugs and contrast materials. It can absorb from skin and gastrointestinal tract and excreted by kidneys (Pejomand, Jalali, Aghdasi, & A.A., 1995). Affected organs by mercuric compounds are nervous system, thyroid gland, reproductive system, kidney, liver, immune and respiratory systems (Boscolo, Antonucci, Volpe, Carmignani, & Di Gioacchino, 2009; Clarkson, 1997; Crinnion, 2000; Diez, 2009; Mahour & Saxena, 2009; Rao & Chhunchha, 2009; Rao, Purohit, & Patel, 2000; Satoh, 2000; Sharma, Kapadia, Fransis, & Rao, 1996; Yanagisawa, 1998). It has been shown that mercuric

* Corresponding Author:

Mehdi Mehdizadeh, PhD

Cellular and Molecular Research Center, Department of Anatomy, Iran University of Medical Sciences, Tehran, Iran

P.O. Box: 15875-1454.

Tel: 0098(21)82944543, Fax: 0098(21)88058689.

E-mail: maranaoo@iums.ac.ir

chloride can induce cell death by oxidative stress and apoptosis in affected organs. Mercuric chloride acts by binding to thiol and sulfhydryl groups of proteins, cause mitochondrial dysfunction, and imparet cell membrane integrity (Boscolo et al., 2009; Chen et al., 2009; Mahboob, Shireen, Atkinson, & Khan, 2001; Rao & Chhunchha, 2009; Rao et al., ; Yanagisawa, 1998; Zalups, 2000).

Chronic intoxication with mercury compounds specially methylated and vapour forms can produce neurobehavioral deficits such as sensory-motor and gating disturbances, ataxia, tremor, and behavioural manifestation in human and animals (Berlin, Fazackerley, & Nordberg, 1969; Clarkson, 1997; Diez, 2009; Yamashita, 1997). Peripheral polyneuropathy and losing of nerve axons is also seen in intoxication with ammoniated mercury (Deleu, Hanssens, Salmy, & Hastie, 1998). Mercury compounds can cross the placental barrier and enter the fetus body (Clarkson, Magos, & Greenwood, 1972; Koos & Longo, 1976). Prenatal poisoning with mercury compounds has been shown to produce neurodevelopmental disturbances; chronic exposure in prenatal period to mercury vapours from amalgam filled teethes and also methyl mercury from fish consumption has been reported to correlate with neurobehavioral

deficits (Clarkson et al., 1972; Koos & Longo, 1976; Myers & Davidson, 1998; Newland, Warfvinge, & Berlin, 1996; Pilonis, Lai, & Gavalchin, 2007; Sikorski & Paszkowski, 1984; Szasz et al., 2002; Yoshida, 2002). However, there is less known about tratogenicity and prenatal neurotoxicity of mercuric chloride in mammals. The purpose of this study was to investigate the effects of intoxication with mercuric chloride on spinal cord of rat embryos in gestational period.

2. Methods

36 adult female Sprague-dawley rats, after formation of vaginal mating plaque (zero day of gestation) were selected, weighted and divided into six groups (3 control and 3 experimental groups). Weight of rats was between 200-270 grams and age was 90 days. Rats maintained in 12 hours dark/light cycle with free access to food and water and 24 degree temperature. Numbers of 3 rats were kept in each clear polycarbonate cage with sawdust bedding. Experimental groups received mercuric chloride [2mg/kg, IP.] (Hajime, Masayuki, Kazuko, & Tukio, 1991)] at 8th, 9 th, and 10th days of gestation and Control groups were injected with normal saline (1ml/kg, IP.) in the same days. (Table 1)

Table 1. Groups, number of rats, and number of embryos were studied

Group	Number of Rats	Injection Day	Injection Dose	Embryonic Age	Number of Embryos	Abortion
Exp-1	6	8	2 mg/kg HgCl ₂	15	47	-
Exp-2	6	9	2 mg/kg HgCl ₂	15	47	-
Exp-3	6	10	2 mg/kg HgCl ₂	15	50	19.3%
Cont-1	6	8	Normal saline	15	49	-
Cont-2	6	9	Normal saline	15	48	-
Cont-3	6	10	Normal saline	15	49	-

NEUROSCIENCE

In 15th day of gestation, rats anesthetized with ketamine (100 mg/kg, IP) and xylazine (5mg/Kg, IP), and embryos were exited from uterus by making a flank section. Embryos were fixed in bovines fixative (6-24 hours) and tissue passage procedures were done. Then 5 micron diameter sections were prepared using a microtome (Leica), stained by H&E method and were studied by a light microscope (Olympus, Japan) (Omidi Ashrafi & Rezaee, 1989; Parivar & Kochesfahani, 1999). Just sections that contain spinal cord were studeid. For morphometric measurments an eye- piece graticule of olym-

pus microscope were used. Length of graticule was 100 units (1 unit was equal to 12.5 micron in $\times 3.2$ and 4 micron in $\times 10$ objective magnification). Diameters of spinal cord, ventricular, mantle and marginal zones were measured, and means were compared by multivariate repeated measure ANOVA test (treatment and day of injection as inter-subject variable and diameter of layers as repeated factor), using SPSS (ver.14) software. Tukey post-hoc analysis was done for revealing differences among groups. P values less than 0.05 were considered significant. In addition to morphometric

analysis, the length (Crown-Rumpt, CR) and weight of embryos were measured (since there was no difference between groups, the results were not shown). Also the cellular shape and arrangement were observed for signs of cell loss and possible apoptosis.

3. Results

19.3% of exited embryos from Exp-3 group (treated in 10th day of gestation) were not alive (abortion).

ANOVA analysis of morphometric measurements between groups showed a significant effect of treatment on four studied zones ($p < 0.05$). Post hoc analysis of results revealed that the diameters of ventricular zone in all mercuric chloride treated groups were increased compare to control groups, while diameters of spinal cord, mantle and marginal zones were decreased ($p < 0.05$). (Table 2)

Analyse of variances for the effect of “day of treatment” on morphometric measurements show any differences between groups. ($p < 0.05$).

Table 2. Mean \pm SEM of spinal cord zones

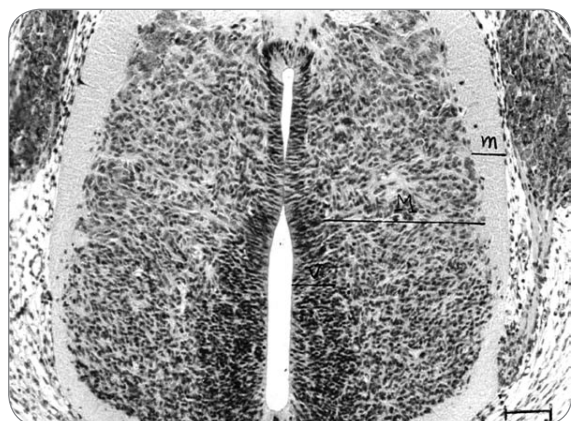
Groups	Spinal Cord Diameter	Ventricular Zone Diameter	Mantle Zone Diameter	Marginal Zone Diameter
Exp-1	362.7 \pm 3.79**	78.9 \pm 1.46**	158.16 \pm 4.53**	37.8 \pm 0.46**
Exp-2	367.5 \pm 2.72**	73.33 \pm 0.61**	153.93 \pm 2.23**	41.6 \pm 0.56**
Exp-3	364.79 \pm 4.65**	71.45 \pm 1.06**	156.36 \pm 3.83**	43.95 \pm 1.00**
Cont-1	397.29 \pm 4.14	37.15 \pm 0.85	188.31 \pm 6.61	60.8 \pm 1.55
Cont-2	395.7 \pm 2.77	39.17 \pm 1.11	185.21 \pm 3.2	61.13 \pm 1.12
Cont-3	396.7 \pm 2.9	38.3 \pm 0.92	187.11 \pm 2.22	63.43 \pm 1.01

** $p < 0.05$

NEURSCIENCE

In microscopic studies of control groups, cellular density, nuclear shape and arrangement, and mitotic division have a normal pattern (Figure 1). On the other hand, in mercuric chloride treated rats, cellular disarrangement with

different orientation of nuclei were seen; further, mitotic division, cell death and extracellular space were increased while cellular density were decreased (Figure 2).



NEURSCIENCE

Figure 1. Micrograph showing a horizontal section of spinal cord in embryos of normal rats (received normal saline). H&E staining. $\times 400$. Bar:100 μ . Cell arrangement is normal. V: ventricular zone; M: mantle zone; m: marginal zone

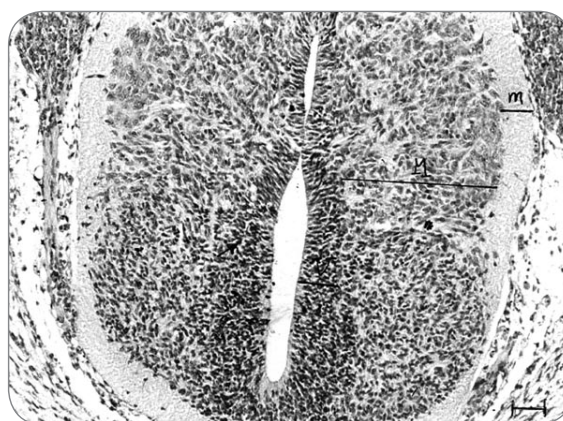

Figure 2. Micrograph showing a horizontal section of spinal cord in embryos of mercuric chloride treated rats. H&E staining. $\times 400$. Bar:100 μ . Note the nuclear disarrangement, cell death and increased extracellular space. V: ventricular zone; M: mantle zone; m: marginal zone : Arrow shows cell death and strike shows extracellular space.

4. Discussion

Results of the present study show that mercuric chloride exposure during gestational period has deleterious effects on neural tube development in rat. as shown above, mercuric chloride reduced the diameter of spinal cord in all its layers (mantle zone and marginal zone) except ventricular zone. There were also some signs of cell death probably due to an apoptotic process in neural tube (increased mitosis in ventricular zone, cellular and nuclear irregularity and disorientation, and increased extracellular space). Apoptosis is a type of cell death that occurs normally (Kerr, Wyllie, & Currie, 1972) in brain during development, and has an important role in the pruning of dendrites and synapses in the way to making well defined circuits in the brain. However, this process is under the tight control of cells. Abnormal apoptosis can be induced in some devastating circumstances such as ischemia and hemostatic imbalance in cell environment. It can also be induced by agents that interfere with function of critical intracellular enzymes. It has been shown that mercury compounds can initiate this lethal process in cells of different organs (Peter, Delma, R., & D., 1999; Shenker, Guo, & Shapiro, 1998; Skenker, Datar, Mansfield, & Shapiro, 1997). In one study, mercuric chloride, induced apoptosis and cell death in vitro, that by increase in time and concentration exposure, number of necrotic cells were also increased and the result was a mixture of necrotic and apoptotic cells (Duncan-Ac, Jones, M.F., Carter, & Laird, 2002).

Mercuric chloride has been shown to damage renal tubular cells with different mechanisms including interference with intracellular thiol metabolism, lipid peroxidation and oxidative stress, impairment in mitochondrial function, effects on intracellular calcium distribution and membranous and structural disturbances (Yanagisawa, 1998; Zalups, 2000). So although not studied directly in our study, based on toxicity properties of mercuric chloride, it may induce apoptosis process in neural tube.

Other finding of the study was that mercuric chloride intoxication, besides teratogenic effects on neural system, can cause embryo death and abortion in rats. As shown this effect of mercuric chloride is dependent on time of exposure and abortion were seen only in rats that received mercuric chloride in 10th day of gestation.

In conclusion, based on the finding of this study, mercuric chloride exposure in prenatal period can produce severe or even lethal deficits in neural tube; and consideration may be undertaken to avoid to exposure to this toxic compound, especially in pregnant women. How-

ever more studies need to revealing the exact cellular mechanisms of this effect of mercuric chloride.

References

- Berlin, M., Fazackerley, J., & Nordberg, G. (1969). The uptake of mercury in the brains of mammals exposed to mercury vapor and to mercuric salts. *Arch Environ Health*, 18, 5, 719-729.
- Boscolo, M., Antonucci, S., Volpe, A. R., Carmignani, M., & Di Gioacchino, M. (2009). Acute mercury intoxication and use of chelating agents. *J Biol Regul Homeost Agents*, 23, 4, 217-223.
- Chen, Y. W., Huang, C. F., Yang, C. Y., Yen, C. C., Tsai, K. S., & Liu, S. H. (2009). Inorganic mercury causes pancreatic beta-cell death via the oxidative stress-induced apoptotic and necrotic pathways. *Toxicol Appl Pharmacol*, 243, 3, 323-331.
- Clarkson, T. W. (1997). The toxicology of mercury. *Crit Rev Clin Lab Sci*, 34, 4, 369-403.
- Clarkson, T. W., Magos, L., & Greenwood, M. R. (1972). The transport of elemental mercury into fetal tissues. *Biol Neonate*, 21, 3, 239-244.
- Crinnion, W. (2000). Environmental medicine, part three: long-term effects of chronic low-dose mercury. *Altern Med Rev*, 5, 3, 209-223.
- Deleu, D., Hanssens, Y., Salmey, H. S., & Hastie, I. (1998). Peripheral polyneuropathy due to chronic use of topical ammoniated mercury. *J. Toxicol. Clin. Toxicol.*, 36, 3, 233-237.
- Diez, S. (2009). Human health effects of methylmercury exposure. *Rev Environ Contam Toxicol*, 198, 111-132.
- Duncan-Ac, K. B., Jones, J. T., M.F., B., Carter, D. E., & Laird, M. E. (2002). Inorganic mercury chloride-induced apoptosis in the cultured porcine renal cell line. *J Pharmacol Exp Ther*, 277, 1726-1732.
- Hajime, M., Masayuki, S., Kazuko, T., & Tukiyo, T. (1991). Rapid changes in concentration of essential elements in organs of rats exposed to mercuric chloride as shown by simultaneous multielemental analysis *Brit J Indust Med* 48, 382-388.
- Kerr, J. F., Wyllie, A. H., & Currie, A. R. (1972). Apoptosis: A basic biological phenomenon with wide ranging implications in tissue kinetics *Br J Cancer*, 26, 239-257.
- Koos, B. J., & Longo, L. D. (1976). Mercury toxicity in the pregnant woman, fetus, and newborn infant. A review. *Am J Obstet Gynecol*, 126, 3, 390-409.
- Mahboob, M., Shireen, K., Atkinson, A., & Khan, A. (2001). Lipid peroxidation and antioxidant enzyme activity in different organs of mice exposed to low level of mercury. *J Environ Sci Health B*, 36, 5, 687-697.

- Mahour, K., & Saxena, P. N. (2009). Assessment of haematotoxic potential of mercuric chloride in rat. *J Environ Biol*, 30,5 Suppl, 927-928.
- Myers, G. J., & Davidson, P. W. (1998). Prenatal methylmercury exposure and children: neurologic, developmental, and behavioral research. *Environ Health Perspect*, 106 Suppl 3, 841-847.
- Newland, M. C., Warfvinge, K., & Berlin, M. (1996). Behavioral consequences of in utero exposure to mercury vapor: alterations in lever-press durations and learning in squirrel monkeys. *Toxicol Appl Pharmacol*, 139, 2, 374-386.
- Omid Ashrafi, A. A., & Rezaee, H. (1989). Histopathology techniquis. Mashad: Jahade daneshgahi.
- Parivar, k., & Kochesfahani, H. (1999). Experimental procedures of histology and embryology Alhossain Publisher.
- Pejomand, A., Jalali, N., Aghdasi, M., & A.A., S. (1995). poisoning (1th ed.). Tehran: Enteshrat.
- Peter, L. G., Delma, T., R., J., & D., A. (1999). Mercuric chlorideinduced apoptosis is dependent on protein syntesis. *Toxicol Lett*,105, 183-195.
- Pilones, K., Lai, Z. W., & Gavalchin, J. (2007). Prenatal HgCl(2) Exposure Alters Fetal Cell Phenotypes. *J Immunotoxicol*, 4, 4, 295-301.
- Rao, M. V., & Chhunchha, B. (2009). Protective role of melatonin against the mercury induced oxidative stress in the rat thyroid. *Food Chem Toxicol*, 48, 1, 7-10.
- Rao, M. V., Purohit, A., & Patel, T. Melatonin protection on mercury-exerted brain toxicity in the rat. *Drug Chem Toxicol*, 33, 2, 209-216.
- Reynolds, J. E. F., Parfitt, K., & Parson, S. A. (1993). Martindale the extra pharmacopoeia (3rd ed.): Williams & Wilkins publisher.
- Satoh, H. (2000). Occupational and environmental toxicology of mercury and its compounds. *Ind Health*, 38, 2, 153-164.
- Sharma, A. K., Kapadia, A. G., Fransis, P., & Rao, M. V. (1996). Reversible effects of mercuric chloride on reproductive organs of the male mouse. *Reprod Toxicol*, 10, 2, 153-159.
- Shenker, B. J., Guo, T. L., & Shapiro, I. M. (1998). Lowlevel methylmercury exposure causes human Tcells to undergo apoptosis: Evidence of mitochondrial dysfunction. *Environ Res*, 77, 149-159.
- Sikorski, R., & Paszkowski, T. (1984). [Embryotoxic and teratogenic effects of mercury]. *Wiad Lek*, 37, 20, 1617-1623.
- Skenker, B. J., Datar, S., Mansfield, K., & Shapiro, I. M. (1997). Induction of apoptosis in human T-cells by organomercuric compounds. A flow cytometric analysis. *Toxicol Appl Pharmacol*, 143, 397-406.
- Szasz, A., Barna, B., Gajda, Z., Galbacs, G., Kirsch-Volders, M., & Szente, M. (2002). Effects of continuous low-dose exposure to organic and inorganic mercury during development on epileptogenicity in rats. *Neurotoxicology*, 23, 2, 197-206.
- Yamashita, T., et al. (1997). Role of nitric oxide in the cerebellar degeneration during methyl mercury intoxication. *Biochimica et biophysica acta*, 1334, 303-311.
- Yanagisawa, H. (1998). [HgCl2-induced acute renal failure and its pathophysiology]. *Nippon Eiseigaku Zasshi*, 52, 4, 618-623.
- Yoshida, M. (2002). Placental to fetal transfer of mercury and fetotoxicity. *Tohoku J Exp Med*, 196, 2, 79-88.
- Zalups, R. K. (2000). Molecular interactions with mercury in the kidney. *Pharmacol Rev*, 52, 1, 113-143.