

Research Paper



Brain MRI Volumetric Assessment of Patients With Multiple Sclerosis: The Volume of Basal Ganglia, Thalamus, and Posterior Fossa

Sima Fallah Arzpeyma¹, Sara Janeshin¹, Niusheh Soofi Afshar¹, Alia Saberi^{2*}, Hamidreza Ghalyanchi Langroodi³, Mohammad Ebrahim Ghaffari⁴, Kamal AmirAshjei⁵

1. Departments of Radiology, School of Medicine, Poursina Hospital, Guilan University of Medical Sciences, Rasht, Iran.

2. Neuroscience Research Center, School of Medicine, Poursina Hospital, Guilan University of Medical Sciences, Rasht, Iran.

3. Unit of Clinical Development Research, Ghaem Int Hospital, Rasht, Iran.

4. Department of Otolaryngology and Head and Neck Surgery, Otorhinolaryngology Research Center, School of Medicine, Amiralmomenin Hospital, Guilan University of Medical Sciences, Rasht, Iran.

5. Unit of Clinical Research Development, Poursina Hospital, Guilan University of Medical Sciences, Rasht, Iran.



Citation Fallah Arzpeyma, S., Janeshin, S., Soofi Afshar, N., Saberi, A., Ghalyanchi Langroodi, H., & Ghaffari, ME., et al. (2023). Brain MRI Volumetric Assessment of Patients With Multiple Sclerosis: The Volume of Basal Ganglia, Thalamus, and Posterior Fossa. *Basic and Clinical Neuroscience*, 14(6), 741-752. <http://dx.doi.org/10.32598/bcn.2023.1324.4>

doi <http://dx.doi.org/10.32598/bcn.2023.1324.4>

**Article info:**

Received: 11 Jun 2

First Revision: 17 Jul 2022

Accepted: 27 Sep 2023

Available Online: 01 Nov 2023

Keywords:

Magnetic resonance imaging,
Volume, Basal ganglia,
Cerebellum, Brainstem,
Multiple sclerosis

ABSTRACT

Introduction: Multiple sclerosis (MS) is an inflammatory demyelinating and neurodegenerative disorder of the central nervous system, which is associated with brain atrophy and volume changes in some brain structures. This study aimed to compare the volume of the basal ganglia, thalamus, cerebellum, and brainstem in patients with relapsing-remitting MS with that of the control group using magnetic resonance imaging (MRI).

Methods: In this cross-sectional study, MRI brain scans were obtained from 25 patients with relapsing-remitting MS and 25 healthy control subjects. Volumetric analyses were performed using Brain Suite software.

Results: The mean age of the MS and the control groups was 33.96 ± 8.75 and 40.40 ± 8.72 , respectively. No statistically significant difference was found in gender ($P=0.747$). The bilateral putamen and caudate nuclei volumes were significantly higher in the case group than in the control group ($P<0.001$). Moreover, lower the volume of the brainstem, cerebellum, bilateral thalamus, and globus pallidus were identified in the MS patients compared to the control group ($P<0.001$). There was an inverse correlation between the disease and treatment duration with the thalamus and cerebellum volume in MS patients ($P=0.001$). Treatment duration also had an inverse correlation with brainstem volume ($P=0.047$).

Conclusion: The volume of some structures of the brain, including globus pallidus, thalamus, cerebellum, and brainstem is lower in MS and can be one of the markers of disease progression and disability among MS patients.

* Corresponding Author:

Alia Saberi, Professor.

Address: Neuroscience Research Center, School of Medicine, Poursina Hospital, Guilan University of Medical Sciences, Rasht, Iran.

Tel: +98 (13) 33368646

E-mail: alia.saberi.1@gmail.com

Highlights

- Due to the degenerative process in multiple sclerosis, some cerebral structures may face volume change.
- The present study demonstrated that the volume of globus pallidus, thalamus, cerebellum, and brainstem is lower in MS patients compared to the controls.

Plain Language Summary

Multiple sclerosis (MS) is defined as an inflammatory disease involving the white matter of the brain, but experience has shown that many non-white matter structures also change in MS. In this study, we aimed to examine some parts of the brain, such as the thalamus, basal ganglia, brainstem, and cerebellum, for volume changes. The results showed that all these structures can have a smaller volume in MS patients than in healthy people. Especially in the case of the thalamus and cerebellum, this difference increases with increasing the disease duration. Changes in the size of these structures can be the result of degeneration of the neurons in these areas. These changes can cause significant disability in patients; however, there may not be significant changes in the number of plaques in patients. Attention to these changes can be essential in interpreting patients' clinical changes, including motor and cognitive disabilities.

1. Introduction

Multiple sclerosis (MS) is the most common chronic disease of the central nervous system in the youth. The prevalence ranges approximately between 50 and 300 per 100000 individuals (Kantarci & Weinschenker, 2005). An estimated, 2.5 million people worldwide are suffering from MS (Marciniewicz et al., 2019). It is also more prevalent in women than in men (Harbo et al., 2013).

It is an inflammatory demyelinating and neurodegenerative disorder affecting the brain and spinal cord and causes physical disability and cognitive dysfunction (Haaga et al., 2009; Bradley, 2008; Saberi & Kazemi 2019). Immunological mechanisms, which damage myelin sheath and impair nerve impulse conduction, serve a key role in the complex pathogenesis of MS. Moreover, axonal degeneration is the cause of the irreversible progression of disability in these patients (Marciniewicz et al., 2019; Filippi et al., 2010). The cause of MS remains unknown yet, despite the gains in knowledge of cellular and molecular biology, immunology, and genetics (Pashenkov et al., 2003).

Considering the course of the disease, MS is classified into several sub-types, which relapsing-remitting MS (RRMS) is the most frequent type (Fauci et al., 2015; Saberi et al., 2018).

The diagnostic process of MS includes clinical and para-clinical exams (Hartung et al., 2015) to prove the dissemination of MS plaques in space and in time and to exclude alternative diagnoses (Yamout et al., 2019). Evoked potentials (Parisi et al., 1998) and magnetic resonance imaging (MRI) (Chen et al., 2016) provide information useful for the diagnosis of the disease. MRI is also a useful tool for monitoring the progression of disease and treatment response. Brain volumetric assessment using MRI offers a helpful clinical assessment of the disease. Such an assessment can predict MS-related disability, with distinct patterns for expanded disability status scale as a measure of physical disability and symbol-digit modalities test as a measure of cognitive disability (D'Hooghe et al., 2019). In addition to lesion load as a marker of disease activity, MRI-measured brain atrophy has been proposed as an important indicator of neurodegeneration in MS patients. The thalamus is also prone to atrophy in the early stages of MS (Bergsland et al., 2012; Datta et al., 2015; De Stefano et al., 2017; Audoin et al., 2006). Also, Putamen's atrophy has been found in the different subtypes of MS, especially in advanced cases (Bergsland et al., 2012; Datta et al., 2015; Bermel et al., 2006; Calabrese et al., 2011; Dolezal et al., 2013; Hagemeyer et al., 2013; Krämer et al., 2015). Several studies have indicated a lower gray matter volume in MS patients than in healthy individuals. The annual rate of brain atrophy is 2-3 fold faster in MS patients than in healthy individuals (Hardmeier et al., 2005; Minagar et al., 2013).

While the majority of studies have focused on brain and spinal atrophy, the brainstem and cerebellum have received very little attention. The brainstem is a frequent location for pathology in MS patients (Ormerod et al., 1987). Many brainstem symptoms might appear early in the course of MS (Magnano et al., 2014; Preziosa et al., 2014). Computed tomography (CT) was used to conduct preliminary research on brainstem atrophy. In a study on 200 MS Patients, 53 cases had brain/cerebellar atrophy, and there was a close link between brainstem shrinkage and brainstem dysfunction (Loizou et al., 1982). CT images, on the other hand, lack the contrast and resolution required for precise assessments; therefore, subsequent investigations have relied on MRI instead (Chivers et al., 2015; Eshaghi et al., 2018). Studies employing MRI to investigate brainstem and cerebellar atrophy have significant contradictions. In certain trials, they showed a volume decrease ranging from 11% (Liptak et al., 2008) to 20.6% (Liu et al., 1999). Several investigations have found no substantial atrophy in these structures in MS patients (Lin et al., 2003).

In the present study, we aimed to evaluate the volume of basal ganglia (caudate, putamen, and globus pallidus), thalamus, cerebellum, and brainstem in MS patients using MRI-based volumetric analysis.

2. Materials and Methods

This cross-sectional study was performed on 25 RRMS patients and 25 healthy subjects in an academic hospital in the north of Iran in 2020.

To determine the sample size, the distribution of the two groups should be considered. The Equation 1 used for this purpose used the difference between the mean volumes of putamen in the two groups. Considering the statistical power of 80%, the error level of 0.05, and the standard deviation equal to 1794 and 1849, $d=1500$, and according to Krämer et al.'s (2015) study, the sample size was calculated as 23.12, which is equal to 24 cases for each group.

$$n = \frac{\left(z_{1-\frac{\alpha}{2}} + z_{1-\beta} \right)^2 (\sigma_1^2 + \sigma_2^2)}{(d)^2} =$$

1.

$$\frac{(1.96 + 0.84)^2 (1794^2 + 1849^2)}{(1500)^2} = 23.12 \cong 24$$

Inclusion criteria: Subjects with RRMS diagnosed by a neurologist based on McDonald's MS criteria (2017) who were referred to a neurology clinic in an academic hospital, with less than 20 years from diagnosis, and aged between 20 and 50 years old were included. The control group also included healthy subjects without MS and without a family history of MS who voluntarily participated in the study.

Exclusion criteria: Subjects with lesions other than MS lesions in the case group and any brain lesions in the control group were excluded from the study. Moreover, subjects with concomitant cerebrovascular diseases, neurodegenerative disorders, psychological disorders, and MS patients with multiple medications and significant MRI artifacts were excluded from the study. Informed consent was obtained from all participants.

Demographic characteristics (age and gender) and clinical data (duration of disease, medication use, and duration of MS medication use) of patients were collected from their records. Demographic characteristics were recorded for the control group.

Brain MRI

Brain MRI was performed for both groups using a scanner with an 18-channel phased array head coil (Siemens Magnetom Avanto 1.5T MRI system, Germany). The imaging protocol included the T1-weighted images (echo time (TE)=12 ms and repetition time (TR)=664 ms). The thin slice images (1 mm) were taken in axial, sagittal, and coronal views.

MRI volumetric analysis

We utilized BrainSuite, version 16a1 an open-source software for processing MRI images, to calculate the volume of structures within the brain. We started by pre-processing MRI images of the brain to ensure that the data were free of artifacts and distortion. This step included skull stripping, motion correction, and intensity normalization. We then used BrainSuite's cerebrum labeling feature to segment the brain into different regions of interest (ROI), like caudate, putamen, globus pallidus, thalamus, cerebellum, and brainstem (segmentation). This allowed us to isolate these structures from the rest of the brain structures. Using the segmented ROIs, we calculated the volume of each structure of interest using BrainSuite's automated volume calculation tool (volume calculation). This tool generates a table showing the volumes of different brain structures in cubic millimeters

(Figure 1). This process was performed by two radiologists (Niusheh Soofi Afshar and Sara Janeshin).

Data analysis

The analysis of covariance (ANCOVA) was used for the quantitative (categorical) variables. The Tukey multiple comparison test was used to compare the mean values between the groups. Pearson's and Spearman's correlation coefficients were also applied. Moreover, to compare qualitative variables, the chi-square and Fisher's exact tests were employed. Data analysis was performed using SPSS software, version 26 at a $P < 0.05$ as significant level.

3. Results

There were 25 MS patients (18 females and seven males) with a Mean \pm SD of age of 33.96 \pm 8.75 years and 25 healthy individuals (19 females and six males) with a Mean \pm SD of age of 40.40 \pm 8.72 years. There was a significant difference in the age of the MS subjects compared to that of the control group ($P=0.01$). There was no significant difference in gender between the two groups ($P=0.74$).

In terms of the disease duration, patients were divided into four groups of 0-5, 6-10, 11-15, and 16-20 years. Most patients had a duration of the disease of 0-5 years (68%, $n=17$). Also, the lowest frequency was spotted among the duration of disease of 16-20 years (4%, $n=1$).

The mean disease duration was 5.58 \pm 4.53 years with a range from six months to 17 years.

Based on the duration of medication use, the patients were divided into three groups of 0-5, 6-10, and 11-15 years. Most MS patients took medications for 0-5 years (72%, $n=18$) and only one patient (4%) used medication for 11-15 years. The mean duration of medication use was 4.68 \pm 3.49 years with a range from six months to 14 years.

Figure 1 compares the bilateral thalamus and basal ganglia volume in the MS and the control groups. There was a significant difference in the volume of the putamen, caudate nuclei, globus pallidus, and thalamus between the two groups. The mean volumes of the putamen and caudate nuclei were higher in the MS patients group, whereas the mean volumes of globus pallidus and thalamus were higher in the control group (Figure 2).

The volume of the brainstem differed significantly between the MS and control groups ($P=0.001$). In the MS group, the mean brainstem volume was lower. There was also a significant difference in cerebellar volume between the MS and control groups. The MS group had a decreased mean cerebellar volume ($P=0.004$) (Figure 3).

Figures 3, 4 and 5 present a correlation between disease duration and treatment duration and the volume of the basal ganglia, thalamus, cerebellum, and brainstem. Significant inverse correlations were identified between

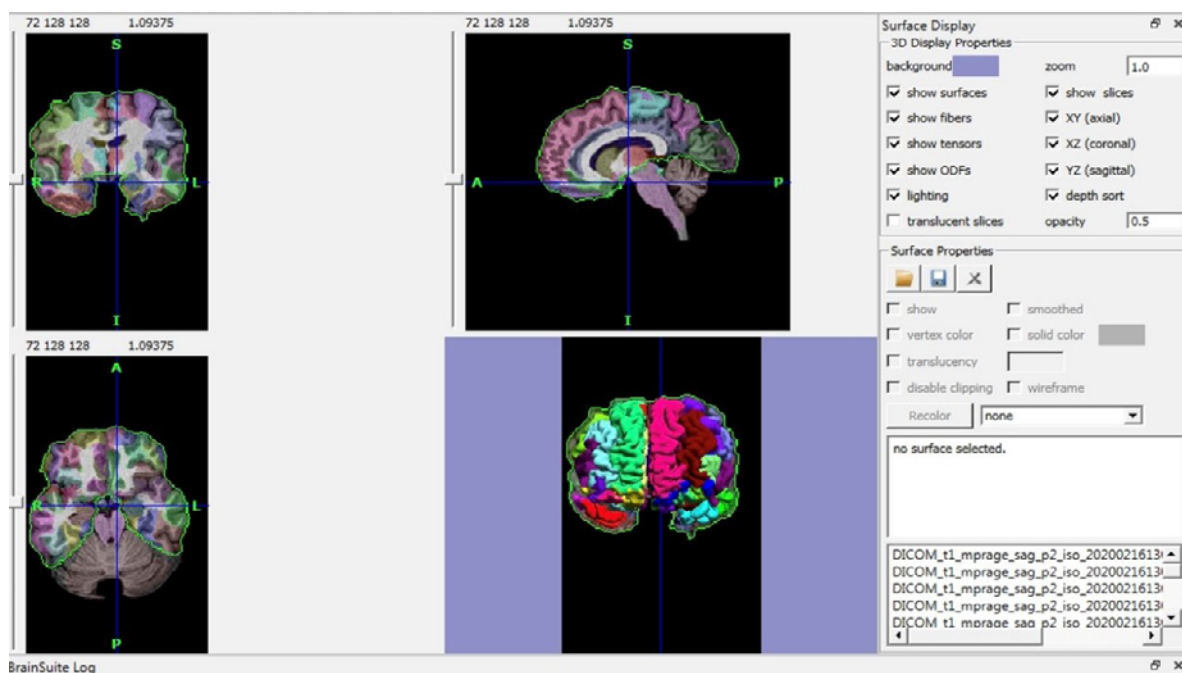
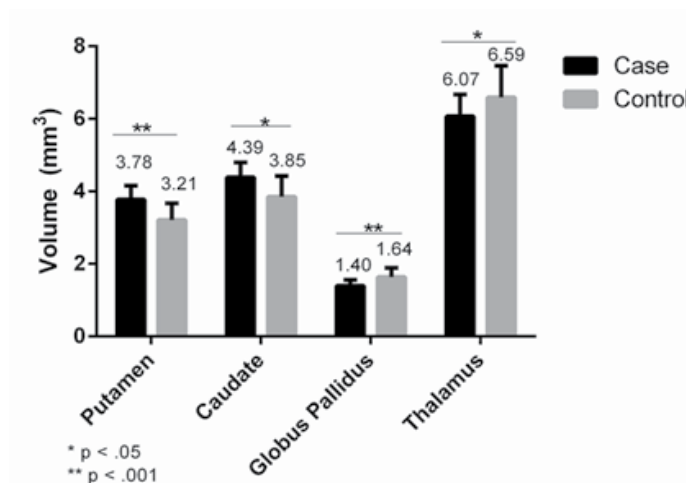


Figure 1. Volumetric assessment of cerebral structure by brainsuite software



NEUROSCIENCE

Figure 2. Comparison of bilateral basal ganglia and thalamic volume in the MS and control groups (Putamen: $P < 0.001$, $F = 18.49$; Caudate: $P = 0.001$, $F = 12.49$; Globus pallidus: $P < 0.001$, $F = 15.30$; Thalamus: $P = 0.009$, $F = 7.43$)

the disease duration and the thalamus and cerebellum volume, and also between the duration of treatment and thalamus, cerebellum, and brainstem volumes. Despite medical therapy, a decrease in the thalamus volume was detected (Figures 4, 5 and 6).

As the age difference between the two groups was significant, the ANCOVA was used to adjust the results according to age.

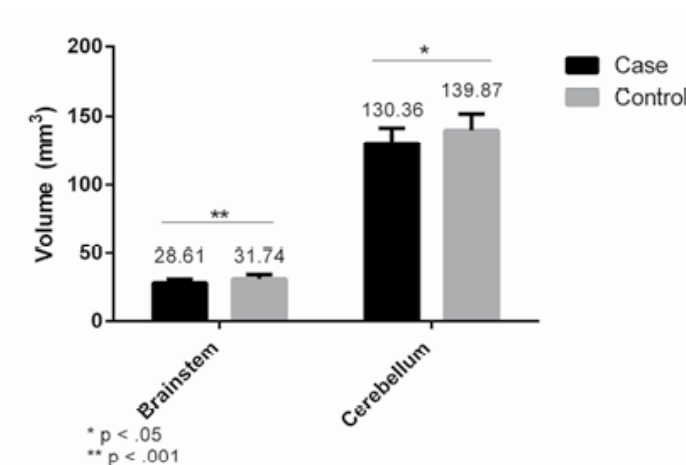
Table 1 shows the relationship between the type of drugs and the studied structures in MS patients. No significant correlation was found between the type of medication and the volume of these structures in any case ($P > 0.05$)

Table 2 presents the correlation between age and studied structure volumes in the MS and the control groups.

Table 3 presents the comparison of the mean volumes of studied structures in men and women in the studied groups. There was no difference in their volumes between men and women in both groups.

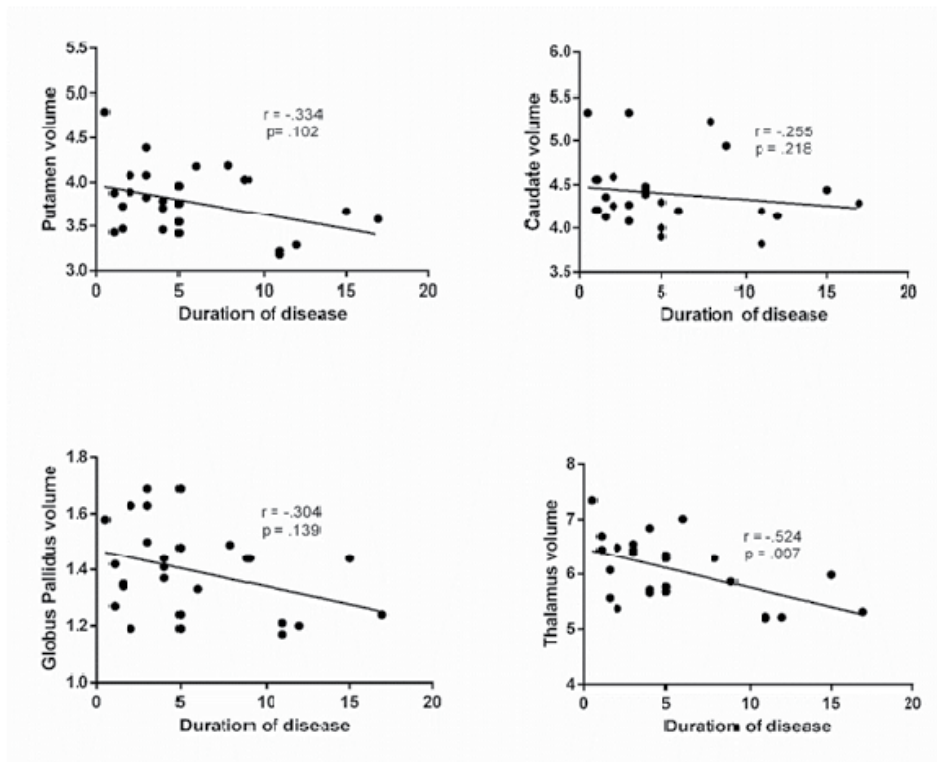
4. Discussion

In the present study, the volume of the globus pallidus and thalamus in MS patients was lower than that of the control group. These findings are consistent with the results of the majority of the studies in this field (Datta et al., 2015; Audoin et al., 2006; Calabrese et al., 2011; Ormerod et al., 1987; Magnano et al., 2014; Preziosa et al., 2014). The bilateral volume of the putamen and caudate nuclei was unexpectedly lower in the controls than in MS patients. In a study by Grimaud et al. (1995) on MS patients, the volume of the thalamus was reduced, while the volume of the putamen and other basal nuclei



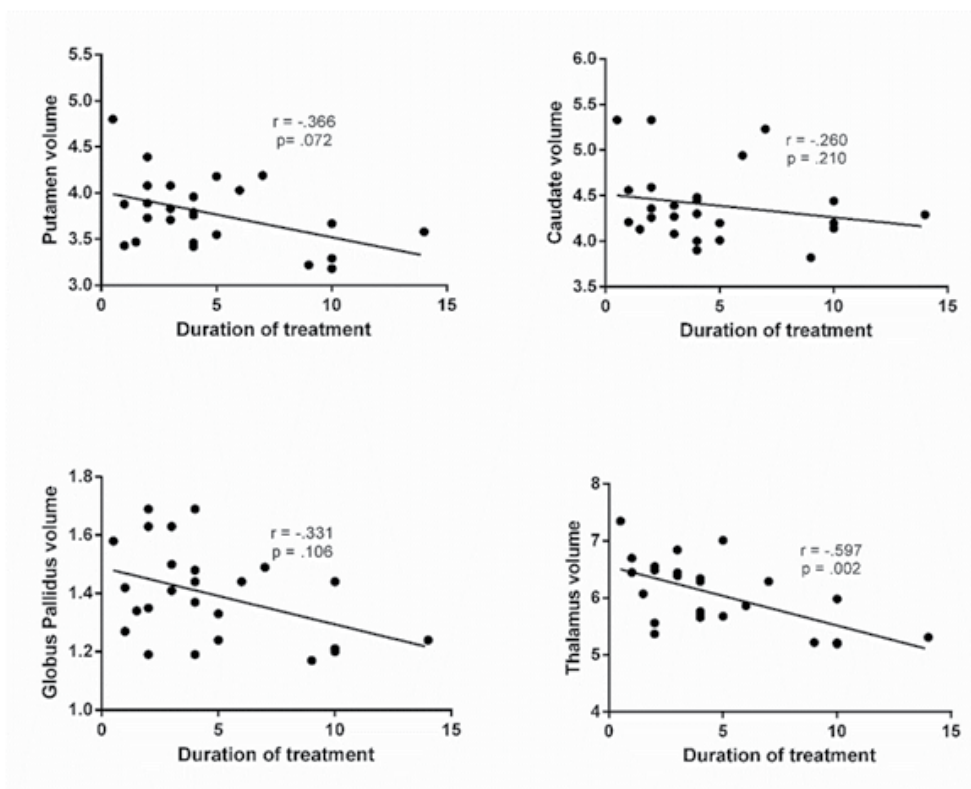
NEUROSCIENCE

Figure 3. Comparison of brainstem and cerebellum volume in the MS and control groups (cerebellum: $P = 0.004$, $F = 9.09$; Brainstem: $P < 0.001$, $F = 14.81$)



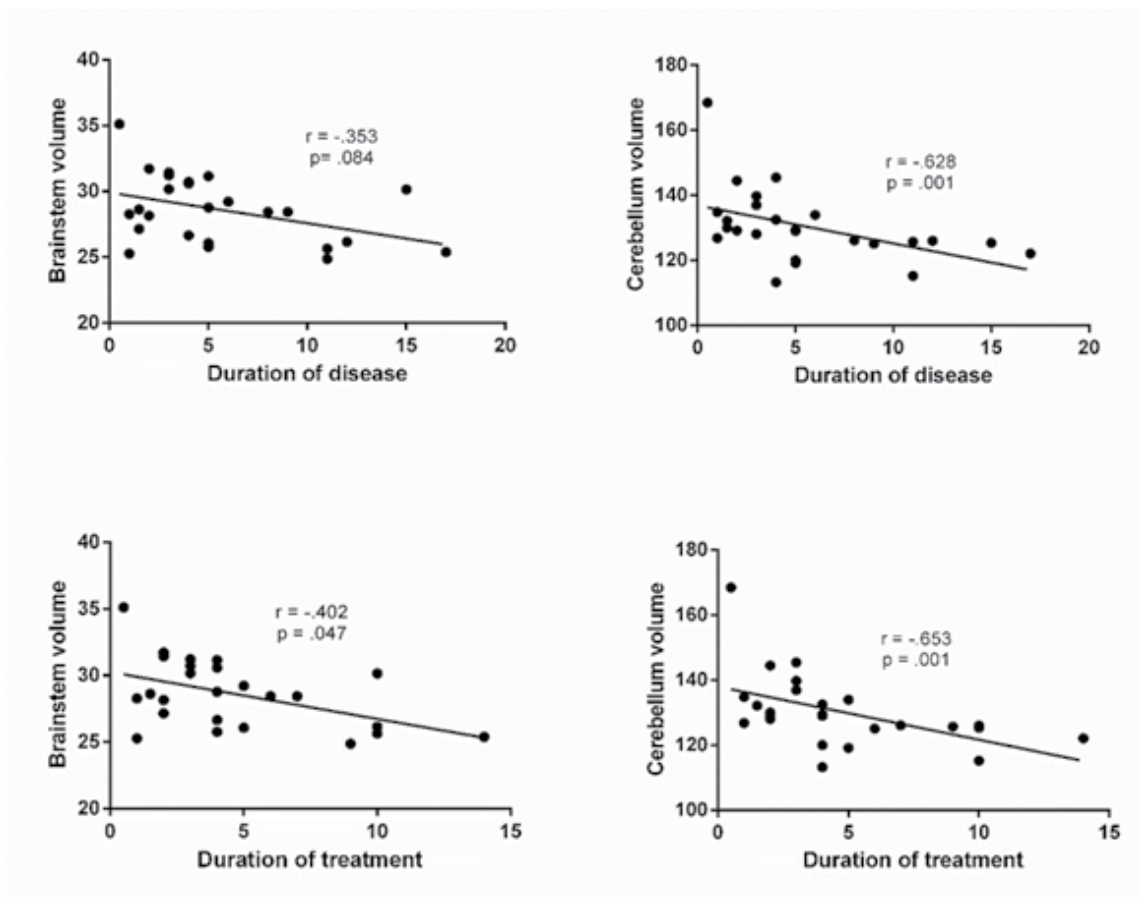
NEURSCIENCE

Figure 4. Correlation between duration of disease and volume of basal ganglia and thalamus (Putamen: $r=-0.334$, $P=0.102$; Caudate: $r=-0.255$, $P=0.218$; Globus Pallidus: $r=-0.304$, $P=0.139$; Thalamus: $r=-0.524$, $P=0.007$)



NEURSCIENCE

Figure 5. Correlation between the duration of treatment and volume of basal ganglia and thalamus (Putamen: $r=-0.366$, $P=0.072$; Caudate: $r=-0.260$, $P=0.210$; Globus pallidus: $r=-0.331$, $P=0.106$; Thalamus: $r=-0.597$, $P=0.00$)



NEURSCIENCE

Figure 6. Correlation between the brainstem and cerebellum volume and duration of disease (brainstem: $r=-0.353$, $P=0.084$, cerebellum: $r=-0.628$, $P=0.001$) and duration of treatment (brainstem: $r=-.402$, $P=0.047$, cerebellum: $r=-0.653$, $P=0.001$)

Table 1. Relationship between the type of drugs and the volume of the basal ganglia and thalamus in the studied MS patients

Brain Region	Drug/Mean±SD (mm ³)				P (F) ^a
	Avonex	Cinnovex	Fingolimod	Glatiramer Acetate	
Putamen	3.47±0.35	3.75±0.26	4.13±0.48	3.71±0.42	0.173 (1.83)
Caudate nucleus	4.08±0.38	4.33±0.36	4.55±0.52	4.47±0.44	0.544 (0.73)
Globus pallidus	1.25±0.12	1.42±0.15	1.38±0.16	1.40±0.18	0.637 (0.57)
Thalamus	5.39±0.24	6.26±0.43	6.42±0.91	5.77±0.48	0.058 (2.91)
Brainstem	26.0±1.62	28.57±2.29	30.67±3.08	28.28±2.47	0.192 (1.73)
Cerebellum	127.86±3.10	134.83±8.5	139.24±19.83	124.53±8.25	0.173 (1.83)

NEURSCIENCE

^aAnalysis of variance (ANOVA).

Table 2. Spearman correlation between age and bilateral basal ganglia volume in MS and control groups

Group	Putamen	Caudate	Globus Pallidus	Thalamus	Brainstem	Cerebellum
Age of MS group	r=-0.169 P=0.420	r=-0.037 P=0.860	r=-0.249 P=0.229	r=-0.086 P=0.681	r=0.31 P=0.132	r=0.253 P=0.222
Age of the control group	r=0.159 P=0.446	r=-0.026 P=0.900	r=0.105 P=0.616	r=-0.144 P=0.492	r=0.127 P=0.546	r=0.002 P=0.994

NEURSCIENCE

Table 3. Comparison between the mean volumes (mm³) of studied structures in men and women in the MS and control groups

Group	Nucleus	Gender/Mean±SD		Independent-samples/t-test	P
		Female	Male		
MS	Putamen	3.37±0.34	3.89±0.47	-0.91	0.368
	Caudate	4.34±0.40	4.51±0.44	-0.90	0.375
	Globus pallidus	1.41±0.16	1.35±0.15	0.81	0.425
	Thalamus	6.14±0.52	5.58±0.76	1.10	0.279
	Brainstem	28.54±2.30	28.80±3.35	0.22	0.824
	Cerebellum	129.37±9.15	132.91±15.96	0.06	0.976
Control	Putamen	3.14±0.42	3.41±0.52	-1.31	0.203
	Caudate nucleus	3.93±0.54	3.59±0.62	1.29	0.207
	Globus pallidus	1.62±0.23	1.66±0.32	-0.26	0.793
	Thalamus	6.46±0.74	7.00±1.15	-1.07	0.322
	Brainstem	30.80±2.88	33.60±3.27	2.01	0.057
	Cerebellum	137.90±10.82	146.09±13.86	1.51	0.976

NEURSCIENCE

showed no difference. These findings may explain transient or persistent sensory disturbances in MS patients, who do not have sensory cortex and subcortical involvement in the parietal lobe but develop sensory impairment due to thalamic atrophy. Interestingly, in a study by Zivadinov et al. (2013), thalamic atrophy was suggested as a criterion for converting clinically isolated syndrome (CIS) to clinically definite MS, and the development of thalamic atrophy was suggested to add new lesions in the dissemination of the time section of the McDonald criteria for MS.

According to the findings of this study, the average volume of the brainstem and cerebellum in the MS group was lower than in the control group, which is consistent with most cerebellar studies (Eshaghi et al., 2018; Liptak et al., 2008; Liu

et al., 1999; Lin et al., 2003; Grimaud et al., 1995; Zivadinov et al., 2103; Bergsland et al., 2019). However, in studies employing MRI to assess brainstem atrophy, there were several inconsistencies. Studies of brainstem atrophy in MS patients compared to controls reported a volume reduction varying between 11% and 20.6% (De Stefano et al., 2017; Liu et al., 1999). However, compared to a comparable age and sex control group, several investigations have found no substantial atrophy in MS patients (Lin et al., 2003). Bergsland et al. (2019) found that patients with MS had a decreased medullary volume. According to Eshaghi et al., (2018) brainstem atrophy may be found in the early stages of cerebral atrophy in MS patients. Also, Chivers et al. (2015) revealed a significant decrease in the volume of midbrain, pons, and medulla oblongata in MS patients compared to healthy people.

Neuroaxonal degeneration was shown to be the cause of a reduction in gray matter volume in the cerebellar cortex and brainstem in MS patients (Bellenberg et al., 2015).

The results of our study showed that the bilateral putamen and caudate nucleus volumes were not reduced compared to the control group. These results were not in agreement with the findings of most of the studies in this field. Most studies have indicated a reduction in the volume of basal ganglia or its some parts, including putamen and caudate nucleus (Audoin et al., 2006; Calabrese et al., 2011; Krämer et al., 2015; Ormerod et al., 1987; Magnano et al., 2014; Preziosa et al., 2014).

In this study, age and gender were not associated with the volume of the studied structures in MS patients. Grimaud et al. (1995) and Drayer et al. (1987) reported no significant correlation between the age of their MS patients and the decreased volume of the basal ganglia. Liu et al. (1999) reported thalamic atrophy in both genders, in addition to cortex and putamen atrophy in males.

Additionally, in the present study, a significant inverse correlation was found between the disease duration and the thalamic, cerebellum, and brainstem volumes. On the other hand, no significant correlation was identified between the disease duration and the volumes of putamen and globus pallidus. Drayer et al. (1987) showed significant correlations between the MS duration and severity and the reduction in basal nuclei volume, which are in agreement with our findings. Contrary to our results, Grimaud et al. (1995) found no significant correlations between disease duration and thalamic volume reduction in MS patients. In the study by Liu et al. (1999) unlike the current investigation, no correlation was found between brainstem and cerebellum volume and illness duration.

The findings of this research also revealed that there was a substantial and inverse correlation between medication usage duration and thalamus, brainstem, and cerebellar volume. The volume of the brainstem and cerebellum diminishes as the length of usage rises. Long-term usage of the medication did not prevent the atrophy and volume loss of these important structures. However, in research by Koudriavtseva et al. (2016) the effects of medicines on the prevention of brain atrophy were larger in the second year of drug use than in the first year, indicating that atrophy prevention is directly and linearly connected to drug use length. According to Branger et al. (2016) the rate of atrophy was significantly greater in patients receiving placebo than in those receiving second-

line disease-modifying drugs after 24 and 48 months of drug therapy. In these studies, also the atrophy and neurodegeneration of cerebral structures progress but a little slower than in the control group. To our knowledge, the disease-modifying drugs that are used for MS, only modify the immune system and prevent “inflammation” and the appearance of inflammatory plaques, and decrease the rate of relapses and new inflammatory lesions, and cannot strongly prevent “neurodegeneration” and atrophy.

Moreover, our findings indicated that there was no correlation between the type of medications and the volume changes of the studied structures.

It seems that this change in brain structure volume in MS is related to neuro-axonal degeneration after the inflammatory process. This has been emphasized by MRI studies and proton MR spectroscopy (by monitoring levels of N acetyl aspartate, a putative marker of axonal integrity) indicating axonal damage in both lesional and non-lesional white matter and also grey matter. Computed measurements of cerebral volumes have been particularly illuminating. Studies have shown that neuro-axonal damage starts in the early stages of the disease and contributes to disability (De Stefano et al., 2003).

The pathologic pathway of neuro-axonal degeneration in MS starts with a reduced metabolism of adenosine triphosphate-generating phosphocreatine, which may impair the astrocytic sodium-potassium pump and lead to a reduced sodium-dependent glutamate uptake. White matter astrocytes in MS appear to be deficient in b2 adrenergic receptors, which are involved in stimulating glycogenolysis and suppressing inducible nitric oxide synthase (NOS₂). Glutamate toxicity, reduced astrocytic glycogenolysis leading to reduced lactate and glutamine production, and enhanced NO levels may all impair axonal mitochondrial metabolism, leading to axonal degeneration. In addition, glutamate-mediated oligodendrocyte damage and impaired myelination caused by a decreased production of N-acetyl aspartate by axonal mitochondria might also contribute to the axonal loss (Cambron et al., 2012).

Also, some studies have suggested the central role of mitochondria in axonal degeneration in MS, which may be relevant for clinical disease progression. Mitochondrial DNA abnormality and mitochondrial dysfunction may be due to primary inflammation in MS or can occur before any inflammation, but contribute to axonal degeneration in MS and disease progression (Saberi & Kazemi, 2019).

This result implies that we should consider these atrophies, besides lesion burden and clinical assessment in the treatment plan and highly potent therapy, with agents directed not only against inflammation but also toward neuronal protection.

Also, the changes in some brain structures could be the imaging biomarkers for disease diagnosis and progression to secondary progressive MS and it is suggested to be included in new versions of MS diagnostic criteria, such as McDonald criteria, especially for defining progressive types.

5. Conclusion

The bilateral volume of the putamen and caudate nuclei did not reduce in MS patients, while globus pallidus, thalamus, cerebellum, and brainstem showed volume loss in MS patients. The disease duration is associated with the thalamic, cerebellum, and brainstem volume reduction.

It is advised that the atrophy of brain regions, such as the brainstem, cerebellum, globus pallidus, and thalamus, be included in the dissemination in time (DIT) portion while revising the McDonald criteria.

Limitations

The limitations of the study were the small sample size, the cross-sectional design, and the lack of longitudinal follow-up. Further future research with a larger sample size and prospective study with follow-up is suggested to determine changes in volume over time and assess their association with disease progression.

Ethical Considerations

Compliance with ethical guidelines

The study was approved by the Ethics Committee of [Guilan University of Medical Sciences](#) (Code: IR.GUMS.REC.1398.458 and Code: IR.GUMS.REC.1398.520). The study process was in compliance with the ethical guidelines of the Declaration of Helsinki 2013.

Funding

This paper was extracted from PhD dissertations of Sara Janeshin and Niusheh Soofi Afshar, approved by Departments of Radiology, School of Medicine, [Guilan University of Medical Sciences](#).

Authors' contributions

Conceptualization and supervision: Alia Saberi and Sima Fallah Arzpeyma, Methodology: Mohammad Ebrahim Ghaffari; Data collection: Sara Janeshin and Niusheh Soofi Afshar; Investigation: Sara Janeshin, Niusheh Soofi Afshar, Alia Saberi and Hamidreza Ghalyanchi Langroodi; Original draft preparation: Kamal AmirAshjei; Review & editing: All authors.

Conflict of interest

The authors declared no conflict of interest.

Acknowledgments

The authors thank the Clinical Research Development Unit of [Poursina Hospital, Guilan University of Medical Sciences](#).

References

- Audoin, B., Davies, G. R., Finisku, L., Chard, D. T., Thompson, A. J., & Miller, D. H. (2006). Localization of grey matter atrophy in early RRMS: A longitudinal study. *Journal of Neurology*, 253(11), 1495–1501. [DOI:10.1007/s00415-006-0264-2] [PMID]
- Bellenberg, B., Schneider, R., Weiler, F., Suchan, B., Haghikia, A., Hoffjan, S., et al. (2015). Cervical cord area is associated with infratentorial grey and white matter volume predominantly in relapsing-remitting multiple sclerosis: A study using semi-automated cord volumetry and voxel-based morphometry. *Multiple Sclerosis and Related Disorders*, 4(3), 264–272. [DOI:10.1016/j.msard.2015.04.003] [PMID]
- Bergsland, N., Horakova, D., Dwyer, M. G., Dolezal, O., Seidl, Z. K., & Vaneckova, M., et al. (2012). Subcortical and cortical gray matter atrophy in a large sample of patients with clinically isolated syndrome and early relapsing-remitting multiple sclerosis. *American Journal of Neuroradiology*, 33(8), 1573–1578. [DOI:10.3174/ajnr.A3086] [PMID] [PMCID]
- Bergsland, N., Jakimovski, D., Weinstock-Guttman, B., & Zivadinov, R. (2019). Automatically segmented medulla oblongata volume as a surrogate for spinal cord atrophy in multiple sclerosis (P5.2-029). *Neurology*, 92(15 Supplement), P5.2-029. [DOI:10.1212/WNL.92.15_supplement.P5.2-029]
- Bermel, R. A., & Bakshi, R. (2006). The measurement and clinical relevance of brain atrophy in multiple sclerosis. *The Lancet. Neurology*, 5(2), 158–170. [DOI:10.1016/S1474-4422(06)70349-0] [PMID]
- Bradley, W. G. (2000). *Neurology in clinical practice: Principles of diagnosis and management*. Oxford: Butterworth-Heinemann. [Link]

- Branger, P., Parienti, J. J., Sormani, M. P., & Defer, G. (2016). The effect of disease-modifying drugs on brain atrophy in relapsing-remitting multiple sclerosis: A meta-analysis. *Plos One*, 11(3), e0149685. [DOI:10.1371/journal.pone.0149685] [PMID] [PMCID]
- Calabrese, M., Rinaldi, F., Mattisi, I., Bernardi, V., Favaretto, A., & Perini, P., et al. (2011). The predictive value of gray matter atrophy in clinically isolated syndromes. *Neurology*, 77(3), 257–263. [DOI:10.1212/WNL.0b013e318220abd4] [PMID]
- Cambron, M., D'Haeseleer, M., Laureys, G., Clinckers, R., Debruynne, J., & De Keyser, J. (2012). White-matter astrocytes, axonal energy metabolism, and axonal degeneration in multiple sclerosis. *Journal of Cerebral Blood Flow and Metabolism*, 32(3), 413–424. [DOI:10.1038/jcbfm.2011.193] [PMID] [PMCID]
- Chen, J. J., Carletti, F., Young, V., Mckean, D., & Quaghebeur, G. (2016). MRI differential diagnosis of suspected multiple sclerosis. *Clinical Radiology*, 71(9), 815–827. [DOI:10.1016/j.crad.2016.05.010] [PMID]
- Chivers, T. R., Constantinescu, C. S., & Tench, C. R. (2015). MRI-based measurement of brain stem cross-sectional area in relapsing-remitting multiple sclerosis. *Journal of Neuroimaging*, 25(6), 1002–1006. [DOI:10.1111/jon.12244] [PMID]
- Datta, S., Staewen, T. D., Cofield, S. S., Cutter, G. R., Lublin, F. D., & Wolinsky, J. S., et al. (2015). Regional gray matter atrophy in relapsing remitting multiple sclerosis: Baseline analysis of multi-center data. *Multiple Sclerosis and Related Disorders*, 4(2), 124–136. [DOI:10.1016/j.msard.2015.01.004] [PMID] [PMCID]
- D'hooghe, M. B., Gielen, J., Van Remoortel, A., D'haeseleer, M., Peeters, E., & Cambron, M., et al. (2019). Single MRI-based volumetric assessment in clinical practice is associated with MS-related disability. *Journal of Magnetic Resonance Imaging*, 49(5), 1312–1321. [DOI:10.1002/jmri.26303] [PMID]
- De Stefano, N., Guidi, L., Stromillo, M. L., Bartolozzi, M. L., & Federico, A. (2003). Imaging neuronal and axonal degeneration in multiple sclerosis. *Neurological Sciences*, 24(Suppl 5), S283–S286. [DOI:10.1007/s10072-003-0175-2] [PMID]
- De Stefano, N., Silva, D. G., & Barnett, M. H. (2017). Effect of fingolimod on brain volume loss in patients with multiple sclerosis. *CNS Drugs*, 31(4), 289–305. [DOI:10.1007/s40263-017-0415-2] [PMID] [PMCID]
- Dolezal, O., Gabelic, T., Horakova, D., Bergsland, N., Dwyer, M. G., & Seidl, Z., et al. (2013). Development of gray matter atrophy in relapsing-remitting multiple sclerosis is not gender dependent: Results of a 5-year follow-up study. *Clinical Neurology and Neurosurgery*, 115(Suppl 1), S42–S48. [DOI:10.1016/j.clineuro.2013.09.020] [PMID]
- Drayer, B., Burger, P., Hurwitz, B., Dawson, D., & Cain, J. (1987). Reduced signal intensity on MR images of thalamus and putamen in multiple sclerosis: Increased iron content?. *American Journal of Roentgenology*, 149(2), 357–363. [DOI:10.2214/ajr.149.2.357] [PMID]
- Eshaghi, A., Marinescu, R. V., Young, A. L., Firth, N. C., Prados, F., & Jorge Cardoso, M., et al. (2018). Progression of regional grey matter atrophy in multiple sclerosis. *Brain*, 141(6), 1665–1677. [DOI:10.1093/brain/awy088] [PMID] [PMCID]
- Fauci, A. S., Hauser, S. L., Longo, D. L., Jameson, J. L., & Loscalzo, J. (2015). *Harrison's principles of internal medicine*. New York: McGraw-Hill Education. [Link]
- Filippi, M., & Agosta, F. (2010). Imaging biomarkers in multiple sclerosis. *Journal of Magnetic Resonance Imaging*, 31(4), 770–788. [DOI:10.1002/jmri.22102] [PMID]
- Grimaud, J., Millar, J., Thorpe, J. W., Moseley, I. F., McDonald, W. L., & Miller, D. H. (1995). Signal intensity on MRI of basal ganglia in multiple sclerosis. *Journal of Neurology, Neurosurgery, and Psychiatry*, 59(3), 306–308. [DOI:10.1136/jnmp.59.3.306] [PMID] [PMCID]
- Harbo, H. F., Gold, R., & Tintoré, M. (2013). Sex and gender issues in multiple sclerosis. *Therapeutic Advances in Neurological Disorders*, 6(4), 237–248. [DOI:10.1177/1756285613488434] [PMID] [PMCID]
- Haaga, J. R., Lanzieri, C. F., & Gilkeson, R. C. (2009). *CT and MR Imaging of the whole body*. London: Mosby. [Link]
- Hagemeyer, J., Yeh, E. A., Brown, M. H., Bergsland, N., Dwyer, M. G., & Carl, E., et al. (2013). Iron content of the pulvinar nucleus of the thalamus is increased in adolescent multiple sclerosis. *Multiple Sclerosis*, 19(5), 567–576. [DOI:10.1177/1352458512459289] [PMID]
- Hardmeier, M., Wagenpfeil, S., Freitag, P., Fisher, E., Rüdick, R. A., & Kooijmans, M., et al. (2005). Rate of brain atrophy in relapsing MS decreases during treatment with IFNbeta-1a. *Neurology*, 64(2), 236–240. [DOI:10.1212/01.WNL.0000149516.30155.B8] [PMID]
- Hartung, H. P., Aktas, O., & Boyko, A. N. (2015). Alemtuzumab: A new therapy for active relapsing-remitting multiple sclerosis. *Multiple Sclerosis*, 21(1), 22–34. [DOI:10.1177/1352458514549398] [PMID] [PMCID]
- Kantarci, O. H., & Weinshenker, B. G. (2005). Natural history of multiple sclerosis. *Neurologic Clinics*, 23(1), 17–38. [DOI:10.1016/j.ncl.2004.10.002] [PMID]
- Koudriavtseva, T., & Mainero, C. (2016). Brain atrophy as a measure of neuroprotective drug effects in multiple sclerosis: Influence of inflammation. *Frontiers in Human Neuroscience*, 10, 226. [DOI:10.3389/fnhum.2016.00226] [PMID] [PMCID]
- Krämer, J., Meuth, S. G., Tenberge, J. G., Schiffler, P., Wiendl, H., & Deppe, M. (2015). Early and degenerative putamen atrophy in multiple sclerosis. *International Journal of Molecular Sciences*, 16(10), 23195–23209. [DOI:10.3390/ijms161023195] [PMID] [PMCID]
- Liptak, Z., Berger, A. M., Sampat, M. P., Charil, A., Felsevalyi, O., & Healy, B. C., et al. (2008). Medulla oblongata volume: A biomarker of spinal cord damage and disability in multiple sclerosis. *American Journal of Neuroradiology*, 29(8), 1465–1470. [DOI:10.3174/ajnr.A1162] [PMID] [PMCID]
- Lin, X., Blumhardt, L. D., & Constantinescu, C. S. (2003). The relationship of brain and cervical cord volume to disability in clinical subtypes of multiple sclerosis: A three-dimensional MRI study. *Acta Neurologica Scandinavica*, 108(6), 401–406. [DOI:10.1034/j.1600-0404.2003.00160.x] [PMID]

- Liu, C., Edwards, S., Gong, Q., Roberts, N., & Blumhardt, L. D. (1999). Three dimensional MRI estimates of brain and spinal cord atrophy in multiple sclerosis. *Journal of Neurology, Neurosurgery, and Psychiatry*, 66(3), 323–330. [DOI:10.1136/jnnp.66.3.323] [PMID] [PMCID]
- Loizou, L. A., Rolfe, E. B., & Hewazy, H. (1982). Cranial computed tomography in the diagnosis of multiple sclerosis. *Journal of Neurology, Neurosurgery, and Psychiatry*, 45(10), 905–912. [DOI:10.1136/jnnp.45.10.905] [PMID] [PMCID]
- Magnano, I., Pes, G. M., Pilurzi, G., Cabboi, M. P., Ginatempo, F., & Giacconi, E., et al. (2014). Exploring brainstem function in multiple sclerosis by combining brainstem reflexes, evoked potentials, clinical and MRI investigations. *Clinical Neurophysiology*, 125(11), 2286–2296. [DOI:10.1016/j.clinph.2014.03.016] [PMID]
- Marciniewicz, E., Podgórski, P., Szaśiadek, M., & Bladowska, J. (2019). The role of MR volumetry in brain atrophy assessment in multiple sclerosis: A review of the literature. *Advances in Clinical and Experimental Medicine*, 28(7), 989–999. [DOI:10.17219/acem/94137] [PMID]
- Minagar, A., Barnett, M. H., Benedict, R. H., Pelletier, D., Pirko, I., & Sahraian, M. A., et al. (2013). The thalamus and multiple sclerosis: Modern views on pathologic, imaging, and clinical aspects. *Neurology*, 80(2), 210–219. [DOI:10.1212/WNL.0b013e31827b910b] [PMID] [PMCID]
- Ormerod, I. E., Miller, D. H., McDonald, W. I., du Boulay, E. P., Rudge, P., & Kendall, B. E., et al. (1987). The role of NMR imaging in the assessment of multiple sclerosis and isolated neurological lesions. A quantitative study. *Brain*, 110(Pt 6), 1579–1616. [DOI:10.1093/brain/110.6.1579] [PMID]
- Parisi, V., Pierelli, F., Restuccia, R., Spadaro, M., Parisi, L., & Colacino, G., et al. (1998). Impaired VEP after photostress response in multiple sclerosis patients previously affected by optic neuritis. *Electroencephalography and Clinical Neurophysiology*, 108(1), 73–79. [DOI:10.1016/S0168-5597(97)00063-4] [PMID]
- Pashenkov, M., Teleshova, N., & Link, H. (2003). Inflammation in the central nervous system: The role of dendritic cells. *Brain Pathology*, 13(1), 23–33. [DOI:10.1111/j.1750-3639.2003.tb00003.x] [PMID] [PMCID]
- Preziosa, P., Rocca, M. A., Mesaros, S., Pagani, E., Drulovic, J., & Stosic-Opincal, T., et al. (2014). Relationship between damage to the cerebellar peduncles and clinical disability in multiple sclerosis. *Radiology*, 271(3), 822–830. [DOI:10.1148/radiol.13132142] [PMID]
- Saberi, A., Akhondzadeh, S., & Kazemi, S. (2018). Infectious agents and different course of multiple sclerosis: A systematic review. *Acta Neurologica Belgica*, 118(3), 361–377. [DOI:10.1007/s13760-018-0976-y] [PMID]
- Saberi A, & Kazemi S. (2019). Mitochondrial dysfunction in multiple sclerosis: A systematic review. *Acta Medica Iranica*. 57(1), 5-16. [DOI:10.18502/acta.v57i1.1748]
- Yamout, B., Sahraian, M., Bohlega, S., Al-Jumah, M., Goueider, R., & Dahdaleh, M., et al. (2020). Consensus recommendations for the diagnosis and treatment of multiple sclerosis: 2019 revisions to the MENACTRIMS guidelines. *Multiple Sclerosis and Related Disorders*, 37, 101459. [DOI:10.1016/j.msard.2019.101459] [PMID]
- Zivadnov, R., Havrdová, E., Bergsland, N., Tyblova, M., Hagemer, J., & Seidl, Z., et al. (2013). Thalamic atrophy is associated with development of clinically definite multiple sclerosis. *Radiology*, 268(3), 831–841. [DOI:10.1148/radiol.13122424] [PMID]