

## Research Paper

## Alterations in Diffusion Tensor Imaging-derived Indices of Auditory Pathway-related Fiber Tracts in Children With Sensorineural Hearing Loss

Samira Sadeghinassab<sup>1</sup>, Ali Reza Eftekhari Moghadam<sup>2</sup>, Nader Saki<sup>3</sup>, Arash Bayat<sup>3,4</sup>, Ghasem Saki<sup>4\*</sup>

1. Department of Anatomical Sciences, Faculty of Medicine, Ahvaz Jundishapur University of Medical Sciences, Ahvaz, Iran.

2. Department of Anatomical Sciences, Faculty of Medicine, Baqiyatallah University of Medical Sciences, Tehran, Iran.

3. Hearing Research Center, Ahvaz Jundishapur University of Medical Sciences, Ahvaz, Iran.

4. Department of Audiology, Faculty of Medicine, Ahvaz Jundishapur University of Medical Sciences, Ahvaz, Iran.



**Citation** Sadeghinassab, S., Eftekhari Moghadam, A. R., Saki, N., Bayat, A., & Saki, Gh. (2023). Alterations in Diffusion Tensor Imaging-derived Indices of Auditory Pathway-related Fiber Tracts in Children With Sensorineural Hearing Loss. *Basic and Clinical Neuroscience*, 14(6), 857-866. <http://dx.doi.org/10.32598/bcn.2023.3593.2>

**doi** <http://dx.doi.org/10.32598/bcn.2023.3593.2>

**Article info:****Received:** 22 Jul 2023**First Revision:** 29 Aug 2023**Accepted:** 18 Sep 2023**Available Online:** 01 Nov 2023**Keywords:**SNHL, DTI, MRI,  
Tractography**ABSTRACT**

**Introduction:** Hearing loss is the most common sensory-neurological defect in humans. The most common hearing impairment is sensorineural hearing loss (SNHL) caused by the inner ear and related nerves. Diffusion tensor imaging (DTI) is an advanced MRI technique that can provide valuable information about auditory neural pathways and their microstructural changes. The present study was designed to investigate the microstructural changes in auditory pathways-related fiber tracts in children with SNHL.

**Methods:** Twenty-two children including 11 subjects with SNHL aged 1-4 years and 11 healthy children were examined as controls. Then, DTI-derived parameters, such as fractional anisotropy (FA), mean diffusivity (MD), axial diffusivity (AxD), and radial diffusivity (RD), and volume of fiber tracts were extracted from the inferior longitudinal fasciculus, acoustic radiation, and uncinata fasciculus.

**Results:** The results showed an increase in MD, RD, and AxD as well as a decrease in FA, volume, and diameter of auditory-pathway-related fiber tracts. Interestingly, there was an increase in the FA of acoustic radiation.

**Conclusion:** White matter connections in the auditory canal decrease and AR integrity increases due to compensatory effects. These probably reflect atrophy or degradation as well as compensatory cross-modal reorganization in the absence of auditory input and the use of sign language.

**\* Corresponding Author:****Ghasem Saki, Professor.****Address:** Department of Anatomical Sciences, Faculty of Medicine, Ahvaz Jundishapur University of Medical Sciences, Ahvaz, Iran.**Tel:** +98 (916) 6181685**E-mail:** [ghasemsaki@yahoo.com](mailto:ghasemsaki@yahoo.com)

## Highlights

- Diffusion tensor imaging (DTI) plays an important role in preoperative planning.
- Anatomical knowledge of the auditory tract is essential for lacrimal drainage surgeries, such as cochlear implantation.
- DTI-based biomarkers for brain changes and allows us to better understand the pathophysiological changes of auditory tract.
- Microstructural changes in the fiber tracts associated with the auditory pathway can distinguish sensorineural hearing loss (SNHL) from healthy subjects.

## Plain Language Summary

Sensorineural hearing loss (SNHL) is the most common type and accounts for the majority of all hearing loss. SNHL is a congenital deficit and refers to any cause of hearing loss due to a pathology of the cochlea, auditory nerve, or central nervous system. One of the chief treatment planning is cochlear implant for these patients. So, it is necessary to evaluate the auditory system by imaging devices such as MRI (magnetic resonance imaging) before treatment. Diffusion tensor imaging tractography, or diffusion tensor imaging (DTI) tractography, is an MRI technique that measures the rate of water diffusion between cells to understand and create a map of the body's internal structures; it is most commonly used to provide imaging of the brain. The purpose of the present research was to assess the auditory system and its nerve routes in children before cochlear implant. This study showed that DT imaging is a novel approach for assessment of children with SNHL before and treatment.

## 1. Introduction

**H**earing loss is one of the most common diseases globally. There are two types of hearing loss: Conductive and sensorineural hearing loss (Zahnert, 2011). Sensorineural hearing loss (SNHL) is the most frequent congenital sensory deficit in children, affecting six in 1000 by age 18 (Huang et al., 2012). It mostly occurs as a result of changes in neural pathways and inner ear dysfunction caused by prenatal and postnatal infection (Chen & Oghalai, 2016). The prevalence of SNHL is about seven per 100,000 for younger children (Wellman et al., 2003), 75% of whom are younger than two years, 15% are 2–5 years, and 10% are older than five years (Koomen et al., 2003). However, SNHL is mainly associated with developmental delay and its underlying pathophysiological mechanisms are not yet well understood. Because sensory input plays a crucial role in human brain functionality, the early hearing deficit can affect the auditory cortex and its white matter fiber tracts, leading to cognitive decline in many domains, including language and learning (Oberge & Lukomski, 2011). Therefore, in order to prevent potential cognitive declines, and better treatment and assessment of cochlear implant candidacy, early detection of the brain microstructural changes is

crucial (Seydell-Greenwald et al., 2014). With the continuous development of magnetic resonance technology, magnetic resonance imaging (MRI) has become a prominent modality to evaluate white matter lesions in the central nervous system. Diffusion tensor imaging (DTI) is an emerging MRI-based modality that can reveal microstructural changes in white matter pathways using specific parameters, such as mean diffusivity (MD) and axial diffusivity (AxD) which are assumed to reflect the breakdown of microstructural barriers and axonal damage (Qian et al., 2018). Radial diffusivity (RD) is specifically associated with myelin degeneration, and fractional anisotropy (FA) measures white matter integrity. DTI plays a key role in detecting early white matter changes associated with hearing loss (Tarabichi et al., 2018). The aim of the present study was to investigate the structural connectivity alterations in the brain white matter tracts of the auditory network in infants with bilateral profound SNHL who are under four years of age.

## 2. Materials and Methods

### Subjects

A total of 22 subjects, including 11 children aged 1–4 years with SNHL leading to bilateral hearing loss and

**Table 1.** Clinical and demographic data of participants (n=10)

Variables	Mean±SD	
	Control Group	Sensorineural Hearing Loss Group
Age (y)	2.36±1.08	2.54±0.8
Male/Female	6/5	6/5

11 age-matched controls were examined in this study. The patients were consecutively recruited. The healthy controls were recruited through local advertisements. Inclusion criteria were no structural abnormalities of the auditory system detected in conventional MRI images before DTI and no previous history of otological surgery. All subjects underwent audiometry, MRI, and DTI scanning (Table 1).

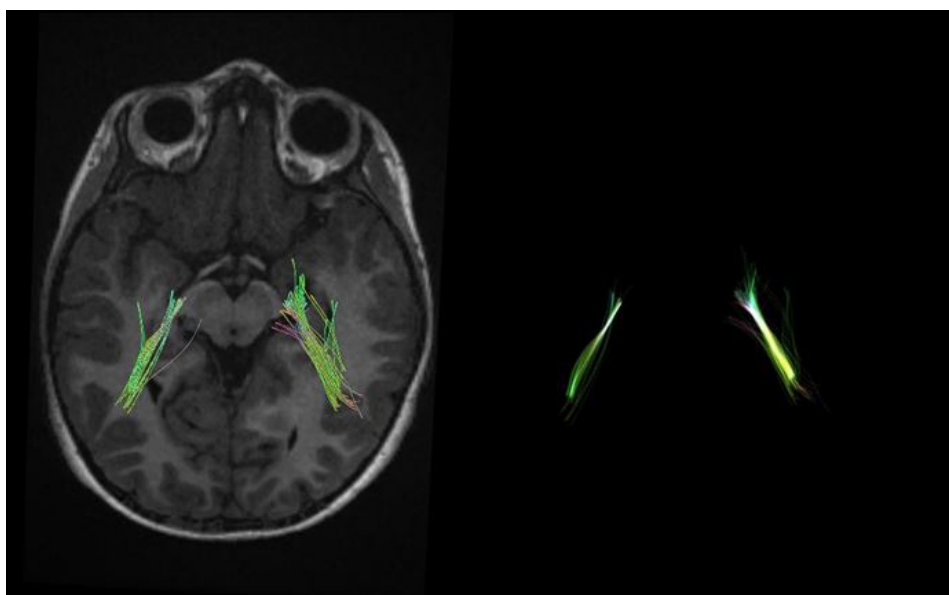
### MRI protocol

Participants underwent a 3D T1-weighted BRAVO protocol, using a 1.5 T Optima MR 450w imager (GE, Milwaukee, WI, USA) with a 12-channel head coil. Whole-brain 3D T1-weighted images were obtained with the following imaging parameters: TR=1002 ms, TE=4.3 ms, voxel size=1×1×1 mm<sup>3</sup>, the field of view (FOV)=220 mm, flip angle=12°, and slice thickness=1 mm with no gaps. DTI data were obtained in the axial plane using a single-shot diffusion-weighted imaging sequence with 64 directions and the following parameters: b-value of 1000 s/mm<sup>2</sup>, TR=9275 ms, TE=79.3 ms,

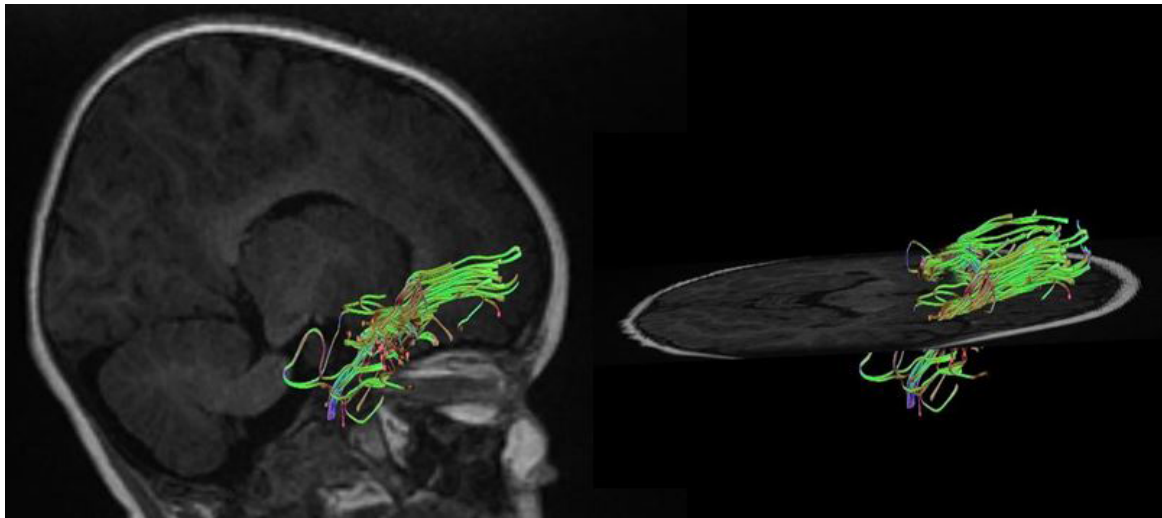
voxel size=1.09×1.09×2.4, 75 slices, slice thickness=2.4 mm, FOV=245 mm, and matrix size=256×256.

### Image processing and tractography

DTI studio (Latest×64 bit version of DTI Studio, Johns Hopkins University) was used for preprocessing and deterministic fiber tracking. The atlas-based tractography was performed. The three main auditory pathway-related fibers, including acoustic radiation (AR), uncinate fasciculus (UF), and inferior longitudinal fasciculus (ILF) were selected. The tractography was done with a step size of 0 mm, minimum fiber length of 30 mm, and turning angle threshold of 60 (Figures 1, 2, 3 and 4). The DTI-derived parameters, FA, MD, axial diffusivity (AxD), and radial diffusivity (RD) were extracted from each tract. Also, the mean length and diameter of all fiber tracts were calculated automatically using morphological assessment of Tensor.



**Figure 1.** An example of the tractography of the acoustic radiation



**Figure 2.** An example of the tractography of the uncinete fasciculus

NEURSCIENCE

### Statistical analysis

Data were analyzed by SPSS software, version 20. The comparisons of demographic and clinical data between two the groups in terms of imaging parameters and proof of hypotheses were performed using the paired t-test. The threshold for establishing significance was set at  $P < 0.05$ .

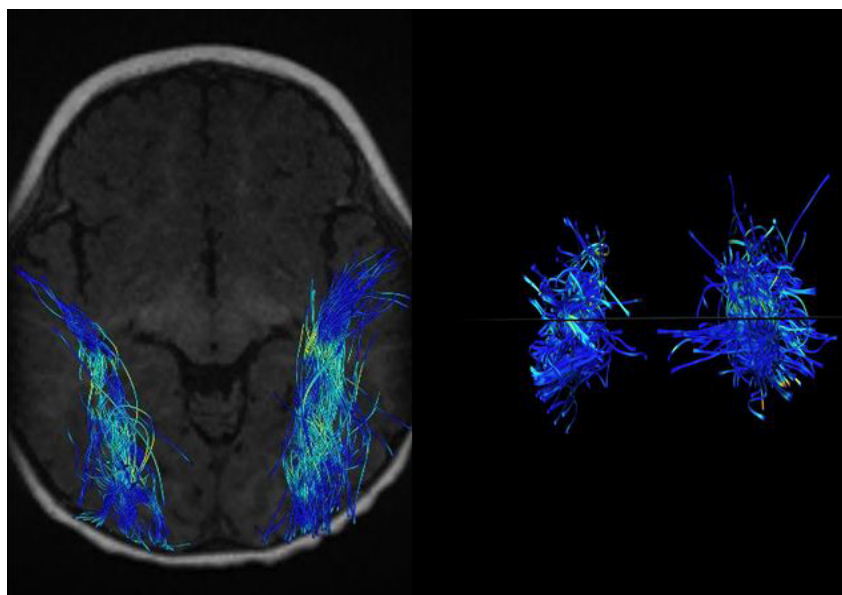
### 3. Results

There was an increase in FA ( $P < 0.0001$ ) a decrease in RD ( $P < 0.05$ ) and a decrease in mean length and volume in the right and left AR tracts ( $P < 0.0009$ ). The decreased volume of right and left UF tracts ( $P < 0.00025$ ), includ-

ing reduced trunk volume ( $P < 0.0001$ ) and reduced mean length ( $P < 0.0001$ ) were evident. A decrease in trunk volume and a decrease in the length ( $P < 0.0011$ ) and diameter of the right and left ILF ( $P < 0.00024$ ) as well as a decrease in FA and an increase in MD and RD parameters were seen in these tracts ( $P < 0.0001$ ) (Table 2, Figure 5).

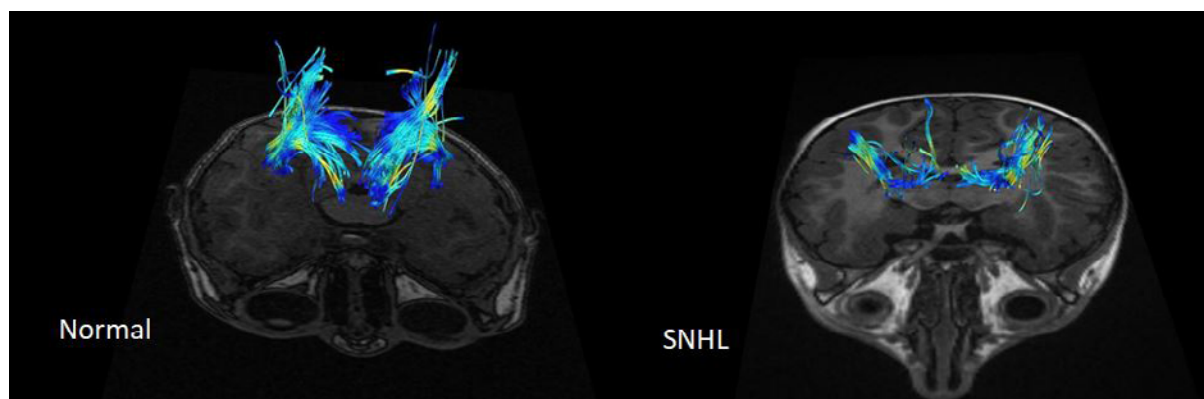
### 4. Discussion

Radiological evaluation of children and adults with SNHL is usually performed by computed tomography (CT) or MRI to examine the temporal and retro-cochlear bone (Sterling et al., 2018). Although conventional and structured MRI is highly sensitive for the diagnosis of congenital anomalies, tumors of the internal auditory



**Figure 3.** An example of the tractography of the inferior longitudinal fasciculus

NEURSCIENCE



NEUROSCIENCE

**Figure 4.** An example of acoustic radiation in patients with SNHL and healthy controls

There is a significant decrease in fiber volume in the left and right AR in a patient with SNHL.

canal, and cochlear nerve anatomy, it does not provide information about the central auditory pathway (Glastonbury et al., 2002). DTI imaging is an MRI-based technique that can provide microstructural information about white matter connections in the central nervous system. The key to the usefulness of this imaging mo-

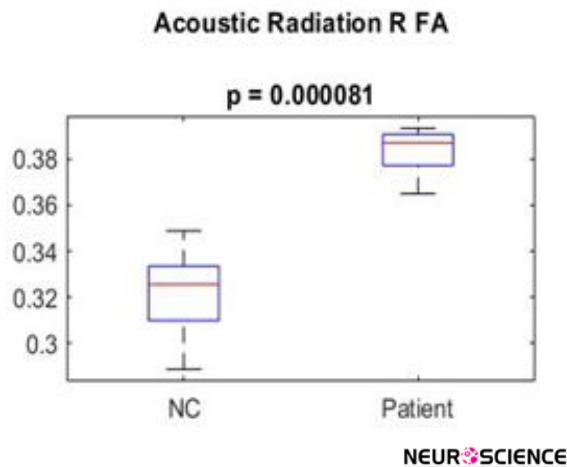
dality is the ability to detect changes and properties of white matter and brain tissue at the microscopic level. Disruption of biological barriers, such as myelin and cell membranes, which normally restrict the motion of water molecules, leads to measurable changes in the diffusion of water molecules (Uluğ et al., 1999). Over the past five

**Table 2.** The significance of the auditory tracts in the normal and SNHL groups

Track Name	Parameter	Unit	Mean		P
			Control Group	SNHL Group	
Acoustic_radiation_R	FA	None	0.32	0.38	8.114E-05
Acoustic_radiation_L	FA	None	0.3	0.35	0.0003913
Acoustic_radiation_R	RD	10-3 mm <sup>2</sup> /sec	0.95	0.78	0.0004991
Acoustic_radiation_L	Length	mm	48.94	38.51	0.0006388
Acoustic_radiation_L	Trunk volume	mm <sup>3</sup>	274.16	85.18	0.0008113
Uncinate_fasciculus_R	Length	mm	59.86	47.39	0.000107
Uncinate_fasciculus_L	Diameter	mm	8.11	7.53	8.152E-05
Uncinate_fasciculus_R	Trunk Volume	mm <sup>3</sup>	135.12	34.74	8.152E-05
Uncinate_fasciculus_R	Volume	mm <sup>3</sup>	2728.15	1848.49	0.0002358
Uncinate_fasciculus_L	Volume	mm <sup>3</sup>	2210.47	1767.72	0.0002358
Inferior_longitudinal_fasciculus_R	MD	10-3 mm <sup>2</sup> /sec	0.91	0.99	8.152E-05
Inferior_longitudinal_fasciculus_R	RD	10-3 mm <sup>2</sup> /sec	0.74	0.85	8.152E-05
Inferior_longitudinal_fasciculus_R	Length	mm	73.13	65.76	0.0010262
Inferior_longitudinal_fasciculus_L	Diameter	mm	10.84	9.34	8.152E-05
Inferior_longitudinal_fasciculus_R	Diameter	mm	11.4	9.63	0.0002358

NEUROSCIENCE

Abbreviation: FA: Fractional anisotropy; MD: Mean diffusivity; RD: Radial diffusivity; SNHL: Sensorineural hearing loss group.



**Figure 5.** The significant difference in fractional anisotropy parameters of the right acoustic radiation between the groups

years, studies on the application of DTI in the evaluation of auditory white matter pathways have been increasing rapidly. The present study was done to evaluate the volume and characteristics of white matter in the auditory pathway-related fiber tracts in children with SNHL.

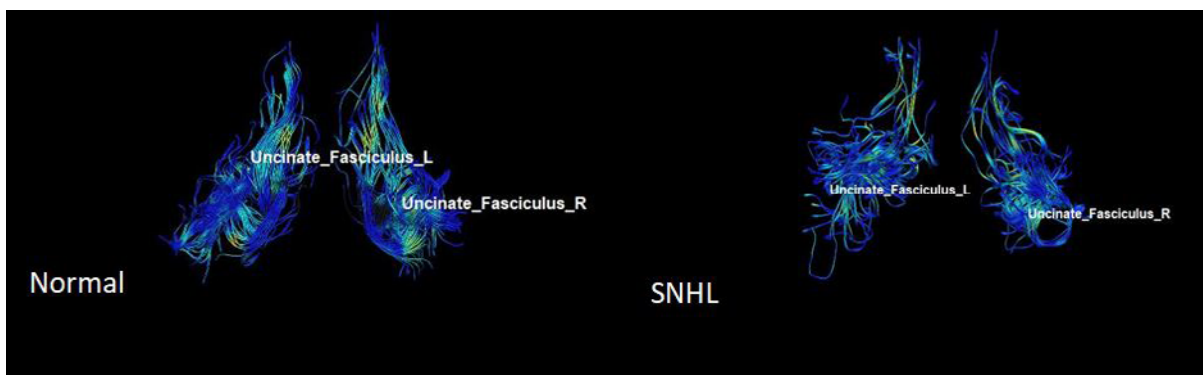
### UF

This area is the largest pathway of the association fiber tract, which connects the frontal lobe to the temporal lobe. This area is said to be part of the limbic system. It plays a major role in language production (Von Der Heide et al., 2013). However, various studies have suggested the role of this tract in the processing of auditory information (Chern et al., 2020). Many studies have shown a decrease in white matter integrity in UF in patients with SNHL (Croll et al., 2020). In a study on the combined DTI and fMRI, a decrease in FA in UF was

found in patients with SNHL aged 1-4 years compared to the normal group (Wang & Fan, 2019; Wang et al., 2020). It should be noted that there are many studies, in which the FA parameter was not significant in differentiating the two groups (Huang et al., 2015). In the present study, which examined the volume and characteristics of UF, a decrease in total volume, trunk volume, and diameter, and also a decrease in length was seen in this tract, which indicates the loss of some nerve fibers due to atrophy in this area. It has been shown that this damage leads to a decrease in the proper functioning of the auditory sense, resulting in hearing impairment. AxD value increased in this area, indicating a decrease in myelin sheath of white matter, atrophy, and integrity in this area (Figure 6).

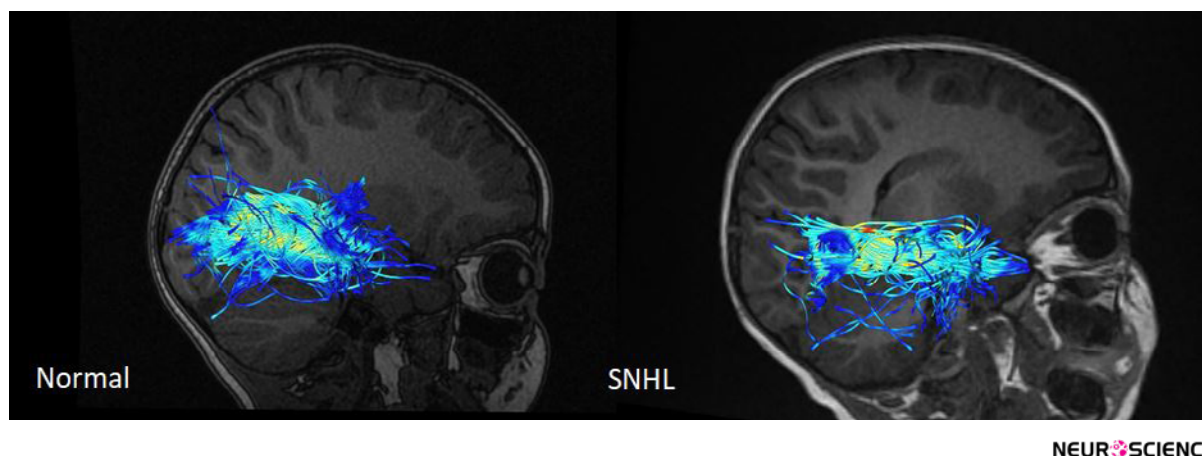
### AR

AR contains a group of highly myelinated axons and is one of the main sensory pathways in the brain that transmit auditory information from the thalamus to the auditory cortex. More precisely, the central auditory pathway begins in the cochlear branch of the eighth nerve of the brain and sends auditory information through the internal capsule to the temporal cortex (Hernández-Zamora & Poblano, 2014). AR has been very difficult to study due to its complex anatomy. With the advent of DTI, the study of this neural pathway in three dimensions has been facilitated, but still, the tractography of this area is challenging (Langguth et al., 2010). In younger patients with congenital deafness, many studies have been performed on volumetric measurement of auditory-related areas (Shibata et al., 2007). However, there are few studies on microstructural alterations in AR in hearing-related diseases, especially SNHL. In addition, AR trac-



**Figure 6.** An example of uncinatus fasciculus in patients with SNHL and healthy controls

The reduction in fiber volume and diameter of uncinatus fasciculus is seen in subjects with SNHL.



**Figure 7.** An example of inferior longitudinal fasciculus in patients with SNHL and healthy controls

A decrease in fiber counts and diameters is seen in patients with SNHL.

tography may be potentially helpful in assessing the integrity of the auditory pathway before and after cochlear implantation. Previous studies have reported a decrease in FA of the AR in patients with SNHL (Huang et al., 2015). In the present study, which examined the volume and diffusion characteristics of AR, the FA parameter showed the highest level of significance in differentiating the two groups from each other. It should be noted that the total volume, trunk volume, and length of this tract decreased, which indicates the existence of a specific pathology in the field of hearing. A very interesting finding in this study was the increase in FA. It indicates an increase in the integrity of this tract, as well as a decrease in MD, AxD, and RD, suggesting an increase in myelin and increased integrity in this area. The cause of this phenomenon can be a compensatory effect against the atrophy of the auditory pathways. To compensate for the effect of the damage, this tract started to remyelinate to be the most efficient with the least volume. There are few studies in this field regarding the increase in FA in AR (Lin et al., 2008).

### ILF

This fiber tract connects the occipital lobe to the anterior part of the temporal lobe. This fiber overlaps with the UF in the anterior part and participates in the transmission of auditory information to the orbitofrontal part of the brain. This fiber is one of the pathways related to visual and linguistic information processing. DTI in combination with magnetoencephalography studies has shown its role in auditory processes and voice-language learning tests (Shin et al., 2019). In other words, ILF integrates information from the auditory and speech areas in the cortex (Mcmaster et al., 2011). Some studies

on SNHL have shown a reduction in FA of ILF (Huang et al., 2015; Wang & Fan 2019). In the present study, a decrease in overall volume, trunk volume, diameter, and length was observed in ILF, indicating a decrease in nerve fibers due to atrophy, leading to hearing disorders. MD, RD, and AxD values increased, indicating a reduction in myelin sheath, atrophy, and integrity in this area (Figure 7).

## 5. Conclusion

In conclusion, the present study showed that microstructural changes in the fiber tracts associated with the auditory pathway can distinguish SNHL from healthy subjects. This study provides DTI-based biomarkers for brain changes and allows us to better understand the pathophysiological changes of related diseases. DTI is an emerging tool for evaluating the affected white matter and compensatory action related to the auditory system in patients with SNHL.

## Ethical Considerations

### Compliance with ethical guidelines

This study was approved by the Ethics Committee of Ahvaz Jundishapur University of Medical Science (Code: IR.AJUMS.MEDICINE.REC.1399.016) and written informed consent was obtained from the parents of all participants before the study.

### Funding

This paper was extracted from master's thesis of Samira Sadeghinasab, approved by Department of Anatomical Science, Faculty of Medicine, Ahvaz Jundishapur

University of Medical Sciences, and was financially supported by the Research Deputy of Ahvaz Jundishapur University of Medical Sciences (Grant No.: HRC-9911).

### Authors' contributions

Conceptualization and supervision: Ghasem Saki and Ali Reza Eftekhari Moghadam; Methodology: Samira Sadeghi; Data collection: Samira Sadeghi, Nader Saki, and Arash Bayat; Data analysis: Ali Reza Eftekhari Moghadam and Samira Sadeghi; Funding acquisition and resources: Ghasem Saki, Nader Saki; Investigation and writing: All authors.

### Conflict of interest

The authors declared no conflict of interest.

### Acknowledgments

The authors would like to thank the head of Medical Imaging Center of Golestan Hospital for its cooperation, and the patients, without whom, this research could not be conducted.

### References

- Chen, M. M., & Oghalai, J. S. (2016). Diagnosis and management of congenital sensorineural hearing loss. *Current Treatment Options in Pediatrics*, 2(3), 256–265. [DOI:10.1007/s40746-016-0056-6] [PMID] [PMCID]
- Chern, A., Irace, A. L., & Golub, J. S. (2020). Mapping the brain effects of hearing loss: The matter of white matter. *JAMA Otolaryngology– Head & Neck Surgery*, 146(11), 1043–1044. [DOI:10.1001/jamaoto.2020.2528] [PMID]
- Croll, P. H., Vernooij, M. W., Reid, R. I., Goedegeure, A., Power, M. C., & Rigtters, S. C., et al. (2020). Hearing loss and microstructural integrity of the brain in a dementia-free older population. *Alzheimer's and Dementia*, 16(11): 1515–23. [DOI:10.1002/alz.12151] [PMID]
- Glastonbury, C. M., Davidson, H. C., Harnsberger, H. R., Butler, J., Kertesz, T. R., & Shelton, C. (2002). Imaging findings of cochlear nerve deficiency. *American Journal of Neuroradiology*, 23(4), 635–643. [PMID] [PMCID]
- Hernández-Zamora, E., & Poblano, A. (2014). [The auditory pathway: Levels of integration of information and principal neurotransmitters (Spanish)]. *Gaceta Medica de Mexico*, 150(5), 450–460. [PMID]
- Huang, B. Y., Zdanski, C., & Castillo, M. (2012). Pediatric sensorineural hearing loss, part 2: Syndromic and acquired causes. *American Journal of Neuroradiology*, 33(3), 399–406. [DOI:10.3174/ajnr.A2499] [PMID] [PMCID]
- Huang, L., Zheng, W., Wu, C., Wei, X., Wu, X., & Wang, Y., et al. (2015). Diffusion tensor imaging of the auditory neural pathway for clinical outcome of cochlear implantation in pediatric congenital sensorineural hearing loss patients. *Plos One*, 10(10), e0140643. [DOI:10.1371/journal.pone.0140643] [PMID] [PMCID]
- Koomen, I., Grobbee, D. E., Roord, J. J., Donders, R., Jennkens-Schinkel, A., & van Furth, A. M. (2003). Hearing loss at school age in survivors of bacterial meningitis: Assessment, incidence, and prediction. *Pediatrics*, 112(5), 1049–1053. [DOI:10.1542/peds.112.5.1049] [PMID]
- Langguth, B., Kleinjung, T., Landgrebe, M., de Ridder, D., & Hajak, G. (2010). rTMS for the treatment of tinnitus: The role of neuronavigation for coil positioning. *Neurophysiologie Clinique*, 40(1), 45–58. [DOI:10.1016/j.neucli.2009.03.001] [PMID]
- Lin, Y., Wang, J., Wu, C., Wai, Y., Yu, J., & Ng, S. (2008). Diffusion tensor imaging of the auditory pathway in sensorineural hearing loss: Changes in radial diffusivity and diffusion anisotropy. *Journal of Magnetic Resonance Imaging*, 28(3), 598–603. [DOI:10.1002/jmri.21464] [PMID]
- Oberg, E., & Lukomski, J. (2011). Executive functioning and the impact of a hearing loss: Performance-based measures and the Behavior Rating Inventory of Executive Function (BRIEF). *Child Neuropsychology*, 17(6), 521–545. [DOI:10.1080/09297049.2011.555760] [PMID]
- Qian, Y., Zhong, S., Hu, G., Kang, H., Wang, L., & Lei, Y. (2018). Sudden Sensorineural Hearing Loss in Children: A Report of 75 Cases. *Otology & neurotology: official publication of the American Otological Society, American Neurotology Society [and] European Academy of Otology and Neurotology*, 39(8), 1018–1024. [DOI:10.1097/MAC.0000000000001891] [PMID]
- Seydell-Greenwald, Anna et al. 2014. "Diffusion Imaging of Auditory and Auditory-Limbic Connectivity in Tinnitus: Preliminary Evidence and Methodological Challenges." *Neural Plasticity* 2014. [DOI:10.1155/2014/145943] [PMID]
- Shibata, D. K. (2007). Differences in brain structure in deaf persons on MR imaging studied with voxel-based morphometry. *American Journal of Neuroradiology*, 28(2), 243–249. [PMID]
- Shin, J., Rowley, J., Chowdhury, R., Jolicoeur, P., Klein, D., & Grova, C., et al. (2019). Inferior longitudinal fasciculus' role in visual processing and language comprehension: A combined MEG-DTI study. *Frontiers in Neuroscience*, 13, 875. [DOI:10.3389/fnins.2019.00875] [PMID] [PMCID]
- Sterling, M. R., Lin, F. R., Jannat-Khah, D. P., Goman, A. M., Echeverria, S. E., & Safford, M. M. (2018). Hearing Loss Among Older Adults With Heart Failure in the United States: Data From the National Health and Nutrition Examination Survey. *JAMA Otolaryngology– Head & Neck Surgery*, 144(3), 273–275. [DOI:10.1001/jamaoto.2017.2979] [PMID]
- Tarabichi, O., Kozin, E. D., Kanumuri, V. V., Barber, S., Ghosh, S., & Sitek, K. R., et al. (2018). Diffusion tensor imaging of central auditory pathways in patients with sensorineural hearing loss: A systematic review. *Otolaryngology–Head and Neck Surgery*, 158(3), 432–442. [DOI:10.1177/0194599817739838] [PMID] [PMCID]
- Uluğ, A. M., Moore, D. F., Bojko, A. S., & Zimmerman, R. D. (1999). Clinical use of diffusion-tensor imaging for diseases causing neuronal and axonal damage. *American Journal of Neuroradiology*, 20(6), 1044–1048. [PMID] [PMCID]



- Von Der Heide, R. J., Skipper, L. M., Klobusicky, E., & Olson, I. R. (2013). Dissecting the uncinete fasciculus: Disorders, controversies and a hypothesis. *Brain*, 136(Pt 6), 1692–1707. [DOI:10.1093/brain/awt094] [PMID] [PMCID]
- Wang, S., Chen, B., Yu, Y., Yang, H., Cui, W., & Li, J., et al. (2019). Alterations of structural and functional connectivity in profound sensorineural hearing loss infants within an early sensitive period: A combined DTI and fMRI study. *Developmental Cognitive Neuroscience*, 38, 100654. [DOI:10.1016/j.dcn.2019.100654] [PMID] [PMCID]
- Wang, S., Chen, B., Yu, Y., Yang, H., Cui, W., & Li, J., et al. (2020). Corrigendum to "alterations of structural and functional connectivity in profound sensorineural hearing loss infants within an early sensitive period: A combined DTI and fMRI study" [Dev. Cogn. Neurosci. 38 (2019) 100654]. *Developmental cognitive neuroscience*, 41, 100689. [DOI:10.1016/j.dcn.2019.100689] [PMID]
- Wellman, M. B., Sommer, D. D., & McKenna, J. (2003). Sensorineural hearing loss in postmeningitic children. *Otology & Neurotology*, 24(6), 907–912. [DOI:10.1097/00129492-200311000-00015] [PMID]
- Zahnert T. (2011). The differential diagnosis of hearing loss. *Deutsches Arzteblatt International*, 108(25), 433–444. [DOI:10.3238/arztebl.2011.0433] [PMID] [PMCID]

This Page Intentionally Left Blank