

Research Paper



Retinal Ganglion Cell Complex in Alzheimer Disease: Comparing Ganglion Cell Complex and Central Macular Thickness in Alzheimer Disease and Healthy Subjects Using Spectral Domain-Optical Coherence Tomography

Zahra Farzinvasht^{1*}, Marzie Abutorabi-Zarchi² , Masoudreza Manaviat¹, Habib Zare Mehrjerdi¹

1. Department of Ophthalmology, School of Medicine, Shahid Sadoughi University of Medical Sciences, Yazd, Iran.

2. Department of Neurology, School of Medicine, Shahid Sadoughi University of Medical Sciences, Yazd, Iran.



Citation: Farzinvasht, Z., Abutorabi-Zarchi, M., Manaviat, M., Zare Mehrjerdi, H., Retinal Ganglion Cell Complex in Alzheimer Disease: Comparing Ganglion Cell Complex and Central Macular Thickness in Alzheimer Disease and Healthy Subjects Using Spectral Domain-Optical Coherence Tomography. *Basic and Clinical Neuroscience*, 13(5), 675-684. <http://dx.doi.org/10.32598/bcn.2021.2040.1>

 <http://dx.doi.org/10.32598/bcn.2021.2040.1>



Article info:

Received: 20 Sep 2019

First Revision: 08 Jun 2021

Accepted: 12 Jun 2021

Available Online: 01 Sep 2022

Keywords:

Alzheimer disease, Optical coherence tomography, Ganglion cell complex, Central macular thickness

ABSTRACT

Introduction: Alzheimer disease (AD) is the most common form of dementia worldwide. The modalities to diagnose AD are generally expensive and limited. Both the central nervous system (CNS) and the retina are derived from the cranial neural crest; therefore, changes in retinal layers may reflect changes in the CNS tissue. Optical coherence tomography (OCT) machine can show delicate retinal layers and is widely used for retinal disorders. This study aims to find a new biomarker to help clinicians diagnose AD via retinal OCT examination.

Methods: After considering the inclusion and exclusion criteria, 25 patients with mild and moderate AD and 25 healthy subjects were enrolled in the study. OCT was done for all eyes. The central macular thickness (CMT) and the ganglion cell complex (GCC) thickness were calculated. The groups were compared using the SPSS software, v. 22.

Results: Both GCC thickness and CMT were significantly decreased in patients with AD when compared to healthy age- and sex-matched individuals.

Conclusion: Retinal changes, specifically CMT and GCC thickness, may reflect the AD process in the brain. OCT can be considered a non-invasive and inexpensive method to help diagnose AD.

* Corresponding Author:

Zahra Farzinvasht, PhD.

Address: Department of Ophthalmology, School of Medicine, Shahid Sadoughi University of Medical Sciences, Yazd, Iran.

Tel: +98 (912) 3722770

E-mail: zahra1142000@yahoo.com

Highlights

- Ocular examination is a good tool to detect Alzheimer disease (AD).

Plain Language Summary

In our study, we provide a new, safe, and relatively inexpensive tool, called optical coherence tomography, for the detection of Alzheimer disease (AD). Optical coherence tomography (OCT) is widely used to evaluate ocular diseases, especially retinal disorders. Because both retina and central nervous system have the same embryologic origin, changes in the ocular structure may show the changes in the central nervous system tissue.

1. Introduction

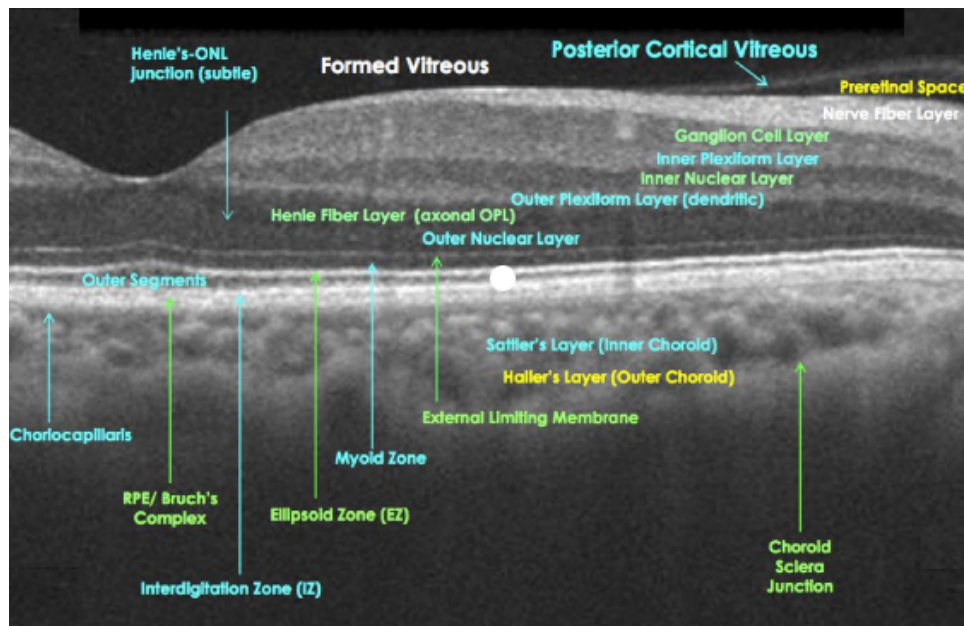
Alzheimer disease (AD) is the most common form of dementia, characterized by the gradual and progressive worsening of cognitive function (Scheltens P et al., 2016). The incidence increases with age, and given the increase in the aging population worldwide, dementia has become a major public health problem. The main pathologic change is the accumulation of Amyloid β (A β) in the Central Nervous System (CNS), which is derived from the abnormal processing of amyloid precursor protein. Intracellular neurofibrillary tangles of tau protein are also observed. Some biomarkers are currently used to diagnose AD. There is a biomarker classification system for the diagnosis of AD, called the A/T/N system (Jack et al., 2018). The letter “A” stands for the aggregation of A β in CNS detected by Cerebrospinal Fluid (CSF) evaluation or Positron Emission Tomography (PET) scan. The letter “T” refers to the aggregated tau protein, which is also shown by CSF analysis or PET scan. And, the letter “N” stands for neuronal injury, detected by PET-scan, structural Magnetic Resonance Imaging (MRI), and CSF total tau protein. These procedures are generally costly and invasive; therefore many of them are not used widely in clinical practice (Lad EM et al., 2018; Grossman Lut, Crenshaw et al., 2010; Thal Li et al., 2006). It is of interest to find a relatively low-cost and non-invasive biomarker to help diagnose and follow up patients with AD.

The retina is an embryological extension of the brain and is derived from the cranial neural tube. A study showed that, in addition to CNS, Alzheimer-related neurodegenerative changes occur in the retina and optic nerve (Hinton et al., 1986). The β -amyloid plaques and neurofibrillary tangles are shown in the retina (Dentchev et al., 2006). Accordingly, any change in the retinal structure may somehow reflect the pathologic process in the brain. Axons of retinal ganglion cells form the Retinal Nerve Fiber Layer (RNFL).

The optic nerve is formed by RNFL and then passes to the brain. Some histopathologic studies have reported the reduction in RNFL and ganglion cell layer (Hinton et al., 1986; Srinivasan and Efron, 2019).

Optical Coherence Tomography (OCT) is a non-invasive, easy-to-use, and relatively low-cost method that can provide a detailed examination of the retinal cells. OCT can distinguish different retinal layers and measure each layer's thickness. A routine OCT exam measures RNFL, which provides the number of neuronal axons, and ganglion cell complex, which shows the number of dendrites and cell bodies of retinal ganglion cells. The Ganglion Cell Complex (GCC) is defined as the sum of the thickness of RNFL, Ganglion Cell Layer (GCL), and the Inner Plexiform Layer (IPL) (Figure 1). These quantitative measures can show the health status of the neuronal structure.

Paquet et al. (2006), Parisi et al. (2001), Berisha et al. (2007), Moschos et al. (2012), Kromer et al. (2014), Larrosa et al. (2014), Polo et al. (2014), Lu et al. (2010), Marziani et al. (2013), Garcia-Martin et al. (2014) and Salobrar-Garcia et al. (2014) have measured the peripapillary RNFL (PRNFL) in patients with AD. Nearly all of these studies have reported PRNFL thinning; however, some recent studies have shown no significant decrease in the PRNFL thickness in patients with AD when compared to the normal population (Domingo Sánchez et al., 2018). The evaluation of GCC thickness in AD was the subject of some other studies. For example, it was shown that IPL thickness decreased earlier than the other layers (Srinivasan and Efron N. 2019; Berisha et al., 2007; Salobrar-Garcia et al., 2014; He XF et al., 2012 and Korneyo-Hamaoui et al., 2011). One study suggested that evaluating the macular GC-IPL thickness may be more sensitive than the RNFL layer in the OCT exam of patients with AD (Gupta et al., 2016; Rui Tao et al., 2019) found that GCC thickness is significantly decreased in AD patients and patients with mild cognitive impairment, compared to healthy subjects. Decreased GC-IPL



NEURSCIENCE

Figure 1. Optical Coherence Tomography (OCT) result of a normal retina. Retinal layers are shown individually. Ganglion Cell Complex (GCC) is composed of Nerve Fiber Layer, Ganglion Cell Layer and Inner Plexiform layer.

thickness is associated with decreased performance and more severe diseases (Cunha et al., 2017).

The macula is a region of the retina that has more than two layers of GCL. Choi et al. (2016), Gao et al. (2015), and Cheung et al. (2015) have shown that macular thickness and macular volume decreases in patients with AD.

In this study, we aim to evaluate the GCC layer and central macular thickness (CMT) in patients with AD and compare it to healthy age- and sex-matched individuals. Even though several studies exist regarding the RNFL thickness in patients with AD, there are relatively few studies about the GCC thickness. Also, there is no previous similar study on Iranian patients with AD.

2. Materials and Methods

This case-control study was conducted in Shahid Saadoughi General Hospital (Yazd Province, Iran). The study was approved by the Medical Research Ethics Committee of the hospital and adhered to the principles of the Declaration of Helsinki. Patients diagnosed with mild to moderate AD, referred by one experienced neurologist, were referred for ophthalmic examination. The diagnosis of dementia was made clinically through minimal mental state examination, in which the patient is assessed and given a score according to their level of education. Patients with scores of 24 to 30 are considered mild, and patients with scores of 18 to 23 are regarded

as the moderate stage of the disease. Neuroimaging and clinical investigation were done to rule out secondary causes of dementia. Any patient with psychiatric disorders, such as depression, anxiety, and psychosis was excluded from the study. The patients with severe AD were also excluded because of possible poor cooperation. Written informed consent letter was obtained from all of the study subjects and or their legal representatives. After obtaining the written informed consent letter, the control group was selected from the ophthalmology clinic. The control group was age- and sex-matched with the case group. Full ophthalmic examination was done for all subjects, including best corrected visual acuity (BCVA), Intraocular Pressure (IOP) by the Goldman tonometer, anterior segment examination with Slit Lamp, and ophthalmoscopy after pupil dilation with a mydriatic drop (1% tropicamide). The subjects with the following conditions were excluded: BCVA less than 0.3 (as determined by the Snellen chart), refraction with spherical equivalent more than +5/-5 diopter, IOP more than 20 mm Hg, significant corneal opacity or dense cataract (because both conditions alter the OCT measurement signal), or any abnormal acquired or congenital finding in the optic nerve and retinal exam. As the presence of glaucoma can alter the results of the OCT exam, any patient with a history of glaucoma or positive family history was also excluded. In addition, any subject with a history of alcohol abuse, previous ocular surgery, and previous blunt or perforating globe trauma were excluded.

After considering the inclusion and exclusion criteria, 25 patients with AD and 25 matched healthy subjects were enrolled in the study. Both eyes of all subjects were tested; therefore, 50 eyes were examined in both groups.

Spectral-domain (SD)-OCT was done using the Spectralis OCT machine (Heidelberg Engineering, Heidelberg, Germany) for all eyes. Images with significant artifacts or low-quality scores were excluded.

The measurements were done using the standard 9 subfields defined by ETDRS (early treatment of diabetic retinopathy study; ETDRS research group investigators, 1991). This standard protocol includes 3 concentric circles centered on the fovea, with diameters of 1, 3, and 6 mm. The 1-3 mm and 3-6 mm rings were divided into superior, inferior, nasal, and temporal quadrants. Accordingly, 9 areas were studied at each exam: superior 3

mm (S3), inferior 3 mm (I3), nasal 3 mm (N3), temporal 3 mm (T3), superior 6 mm (S6), inferior 6 mm (I6), nasal 6 mm (N6), temporal 6 mm (T6), and center of the macula (C) (Figure 2).

GCC thickness was defined as the sum of RNFL, GCL, and IPL. These layers were automatically segmented and their thickness was measured. Because the GCC is naturally thin at the fovea, GCC thickness measurements were not done in the central 1 mm circle. In this area, the CMT was measured instead.

The statistical analysis was performed using the SPSS software, version 22 (SPSS Inc, Chicago, IL, US). Categorical data were presented as frequencies by percentage and continuous data were presented as Standard Deviation (SD) and mean value. The student t test was used

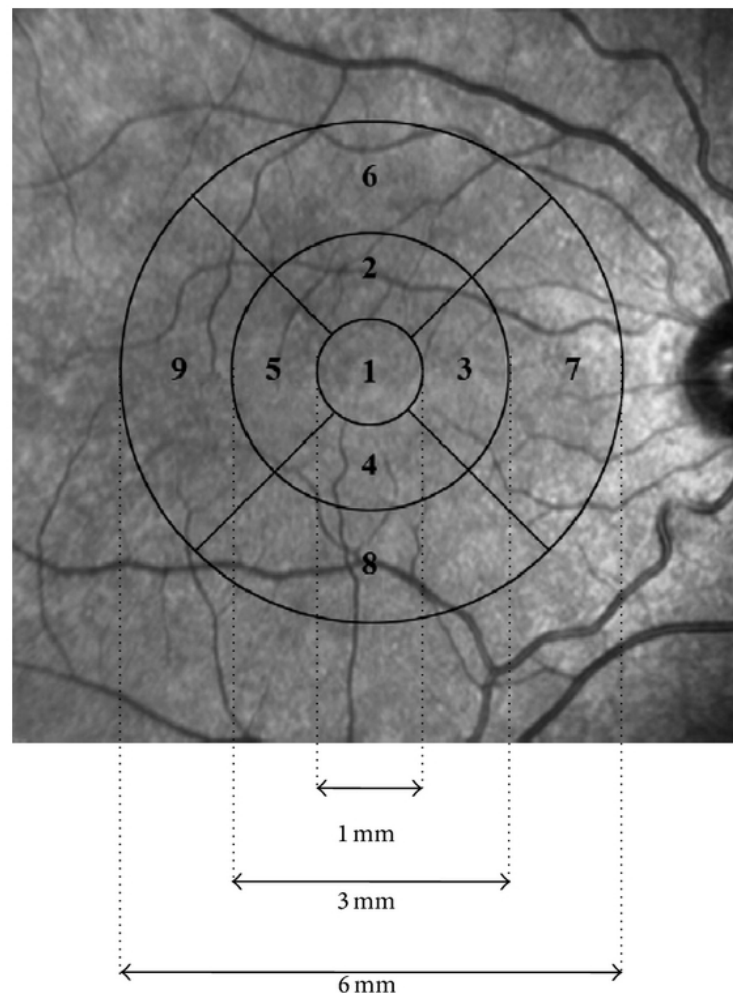


Figure 2. ETDRS standard grid used for retinal thickness report

NEURSCIENCE

1: central 1mm, 2: Superior 3mm (S3), 3: Nasal 3mm (N3), 4: Inferior 3mm (I3), 5: Temporal 3mm (T3), 6: Superior 6mm (S6), 7: Nasal 6mm (N6), 8: Inferior 6mm (I6), 9: Temporal 6mm (T6).

to compare the results between the two eyes, and the P value of less than 0.05 was considered significant.

3. Results

Patient's demographics and clinical characteristics

A total of 25 patients with AD (50 eyes) were included in this study. In addition, 25 healthy subjects (50 eyes) were enrolled as the control. In the case group, 8 patients (32%) were male and 17 patients (68%) were female. The female-to-male ratio in the control group was the same, with a P value of 1. The mean age of patients with AD was 80.44 years (SD=8.66). The mean age of the control group was 79.64 years (SD=9.3). The P value was 0.757, showing that there is no significant difference between the two groups (Table 1). In the case group, 2 patients (8%) had mild AD and 23 patients (92%) had moderate AD.

Findings of spectral domain optical coherence tomography

The mean CMT was 265.15 μ in the healthy group (SD=16.30), compared to the mean CMT of 233.60 μ in the case group (SD=13.55) (Table 2). The P value was 0.0001, showing a significant decrease in CMT in patients with AD.

The mean GCC thickness in the N3 area was 111.43 μ (SD=10.67) in healthy individuals and 92.10 μ (SD=11.29) in AD patients. Mean GCC thickness in the T3 area was 104.94 μ (SD=7.56) in the control group and 89.42 μ (SD=8.16) in the AD group. The mean thickness of GCC in the S3 area was 113.78 μ (SD=9.17) in the control group and 93.03 μ (SD=12.83) in AD patients. The mean GCC thickness was 109.35 μ (SD=13.14) in the I3 area in healthy subjects and 95.70 μ (SD=12.81) in the AD group. The P value for areas N3, T3, and S3 was 0.0001, and for the I3 area was 0.001.

Table 1. Demographics of patients and controls.

Variable	Statistic	Alzheimer	Control	P
	No.	25	25	
Age	Mean \pm SD	80.44 \pm 8.86	79.64 \pm 9.30	0.757
	Min, Median, Max	58, 84, 93	61, 82, 94	
Female gender	Number (%)	17 (68%)	17 (68%)	1

NEURSCIENCE

Table 2. CMT and GCC thickness in patients with Alzheimer's Disease and controls

Location	Mean \pm SD		P
	Alzheimer	Control	
Center (CMT)	233.60 \pm 13.55	265.15 \pm 16.30	0.0001
S3	93.03 \pm 12.83	113.78 \pm 9.17	0.0001
I3	95.70 \pm 12.81	109.35 \pm 13.14	0.001
N3	92.10 \pm 11.29	111.43 \pm 10.67	0.0001
T3	89.42 \pm 9.16	104.94 \pm 7.56	0.0001
S6	82.72 \pm 12.90	93.37 \pm 11.52	0.003
I6	82.50 \pm 10.60	94.72 \pm 16.28	0.003
N6	90.03 \pm 12.70	106.63 \pm 11.89	0.0001
T6	78.45 \pm 9.12	86.00 \pm 10.54	0.009

NEURSCIENCE

The mean GCC thickness in the control group in the N6 area was 106.63 μ (SD=11.89) and 90.03 μ (SD=12.70) in AD patients. The mean thickness of GCC in the T6 area was 86 μ (SD=10.54) in the healthy group and 74.45 μ (SD=9.12) in AD patients. The mean GCC thickness in the S6 area was 93.37 μ (SD=11.52) in the control group and 82.72 μ (SD=12.90) in the case group. The mean thickness of GCC in the I6 area was 94.72 μ (SD=16.28) in the control group and 82.50 μ (SD=10.60) in AD patients. The P value was 0.0001 for the N6 area, 0.009 for the T6 area, and 0.003 for S6 and I6 areas (Table 2). As the results demonstrate, the difference in GCC thickness between the healthy group and the case group reached statistical significance in all areas.

4. Discussion

It is proved that in AD, degenerative changes occur in all parts of the visual system. Deposition of A β throughout the retina, retinal vasculature, and choroid was shown in histopathological studies. The A β deposits mainly in the inner retina and optic disc (London et al., 2013; Dentchev et al., 2006). This deposition is found to be toxic for the retinal ganglion cell neurons.

The modalities of diagnosis in AD are expensive and limited by low sensitivity and specificity. Up to now, there is no proven biomarker for the diagnosis of AD (Kwon et al., 2017; Gharbiya et al., 2014; van de Kreeke et al., 2019). It seems that the evaluation of the retina can provide a useful biomarker to detect neuronal changes in the CNS. OCT is a non-invasive device that can provide a detailed evaluation of retinal layers. OCT is widely used in the diagnosis and following up the patients with retinal disorders. This modality enables the physician to evaluate and quantitatively assess each retinal layer. The optic nerve is made of RNFL, the axons of ganglion cells, and then passes to the brain to connect to the lateral geniculate body. There is a theory that the retrograde degeneration of axons from the brain can alter the structure of retinal ganglion cells (Domingo Sánchez, et al., 2018). Therefore, OCT seems a potentially good device to detect pathologic processes in CNS, such as AD.

OCT can measure RNFL, GCC, and CMT, providing objective measurement of ganglion cell bodies and their dendrites and axons. As mentioned in the introduction, peripapillary RNFL thickness was previously reported to be decreased in AD. Macular thickness and macular volume were also shown to be decreased in patients with Cheung et al. (2015) and Lad EM et al. (2018) have reported a significant reduction of GCC thickness in patients with AD when compared to healthy ones. Some

studies have shown that IPL thickness decreased earlier than the other layers (Paquet et al., 2007; Moschos et al., 2017; He XF et al., 2012; Koronyo-Hamaoui et al., 2011; Gupta et al., 2016). Macular GC-IPL thickness may be more sensitive than the RNFL layer in evaluating AD patients (Cunha et al., 2016). Van der Kreeke et al. (2019) did not find any significant changes in the GC-IPL thickness between A β positive and negative individuals. Rui Tao et al. (2019) found that GCC thickness is significantly decreased in AD patients and also in patients with mild cognitive impairment. They also found a remarkable association between brain volume and retinal changes. Marziani et al. (2013) reported significant GCC reduction in patients with AD when compared to healthy subjects. Cheung et al. (2015) measured the sum of GCL and IPL and reported a significant decrease in the thickness of these layers in AD patients. Choi et al. (2016) also measured the macular ganglion cell-IPL layer thickness and found that the decrease of this layer's thickness is associated with clinical disease progression. Ganglion cell loss begins in the macula during the degenerative process, possibly because of the high retinal ganglion cell density in this region (Curcio, Allen, 1990). This observation was proved by histopathological studies (Blanks, Torigoe, Hinto, Blanks, 1996). In a study on a mouse model of AD by Williams et al. (2013), changes in the dendritic of retinal ganglion cells occurred before cell loss, suggesting the use of inner retinal layers for the detection of neurodegeneration. Our results were consistent with the results of the previous studies.

CMT shows the health status of the retinal neurons. In our study, CMT was significantly decreased in patients with AD compared to healthy subjects. This is consistent with many studies (Choi SH et al., 2016; Gao et al., 2015; Cheung et al., 2015).

To our knowledge, this is the first study evaluating GCC thickness by OCT in Iranian patients with AD. The use of OCT is not popular among Iranian neurologists for the detection or following up the neurologic disorders. Therefore, this study may help neurologists to use a non-invasive, easy-to-use, and relatively low-cost device to diagnose AD, in conjunction with ophthalmological consult.

Our study faced some limitations. Firstly, the sample size was relatively small to detect the difference between patients and the healthy group. Secondly, although we excluded patients with signs of glaucomatous optic neuropathy or IOP more than 20 mm Hg, this cannot completely exclude glaucoma patients because the patients did not take a visual field test. Thirdly, the control group did not undergo extensive neurologic testing to rule out

early or preclinical AD. Fourthly, most of our patients had moderate AD, limiting the study to detect possible early changes in patients with mild AD. In the moderate stages of AD, the diagnosis is made with little challenges, and more challenges are encountered in the diagnosis of mild cognitive impairment. Accordingly, further studies are needed to target this group of patients. Finally, we did not assess the relationship between other variables, such as the functional assessment staging score with GCC thickness, which can be considered in future studies.

The use of OCT markers in AD patients may also be limited because of poor patient compliance due to cognitive impairment. The common ocular conditions occurring in older age, for example, age-related macular degeneration, glaucoma, dense cataract, or any retinal complications of other systemic diseases, such as diabetic retinopathy, can interfere with the interpretation of OCT results. The use of OCT to detect changes because of AD may be limited as a severely dense cataract, dense corneal opacity, vitreous hemorrhage, and any other ocular condition can interfere with the OCT signal. The presence of any congenital retinal abnormality can also limit the use of this technology.

5. Conclusion

In conclusion, in the present study, we evaluated and compared the thickness of GCC and CMT via OCT in patients with AD and healthy age- and sex-matched controls. To the best of our knowledge, this is the first OCT study regarding AD effects on the retina in Iran. Our results show significant thinning of GCC and CMT in AD patients compared to the control group.

Larger sample size is needed for better evaluation of OCT parameters in AD. It is better to evaluate patients with a mild degree of AD, because this may help to detect possible early AD-related changes in the retina. Follow-up studies are also needed to evaluate the changes in retinal OCT over time.

Ethical Considerations

Compliance with ethical guidelines

All ethical principles are considered in this article. The participants were informed of the purpose of the research and its implementation stages. They were also assured about the confidentiality of their information and were free to leave the study whenever they wished, and if desired, the research results would be available to them.

Funding

This research did not receive any grant from funding agencies in the public, commercial, or non-profit sectors.

Authors' contributions

Resources: All authors; Supervision: Masoudreza Manaviat and Zahra Farzinvasht.

Conflict of interest

The authors declared no conflict of interest.

References:

- Berisha, F., Feke, G. T., Trempe, C. L., McMeel, J. W., & Schepens, C. L. (2007). Retinal abnormalities in early Alzheimer's disease. *Investigative Ophthalmology & Visual Science*, 48(5), 2285–2289. [PMID]
- Blanks, J. C., Torigoe, Y., Hinton, D. R., & Blanks, R. H. (1996). Retinal pathology in Alzheimer's disease. I. Ganglion cell loss in foveal/parafoveal retina. *Neurobiology of Aging*, 17(3), 377–384. [DOI:10.1016/0197-4580(96)00010-3]
- Cheung, C. Y., Ong, Y. T., Hilal, S., Ikram, M. K., Low, S., & Ong, Y. L., et al. (2015). Retinal ganglion cell analysis using high-definition optical coherence tomography in patients with mild cognitive impairment and Alzheimer's disease. *Journal of Alzheimer's Disease: JAD*, 45(1), 45–56. [PMID]
- Choi, S. H., Park, S. J., & Kim, N. R. (2016). Macular ganglion cell -inner plexiform layer thickness is associated with clinical progression in mild cognitive impairment and Alzheimers disease. *PloS one*, 11(9), e0162202. [PMID] [PMCID]
- Cunha, J. P., Moura-Coelho, N., Proença, R. P., Dias-Santos, A., Ferreira, J., & Louro, C., et al. (2016). Alzheimer's disease: A review of its visual system neuropathology. Optical coherence tomography-a potential role as a study tool in vivo. *Graefe's Archive for Clinical and Experimental Ophthalmology = Albrecht von Graefes Archiv fur Klinische und Experimentelle Ophthalmologie*, 254(11), 2079–2092. [PMID]
- Curcio, C. A., & Allen, K. A. (1990). Topography of ganglion cells in human retina. *The Journal of Comparative Neurology*, 300(1), 5–25. [PMID]
- Cunha, J. P., Proença, R., Dias-Santos, A., Almeida, R., Águas, H., & Alves, M., et al. (2017). OCT in Alzheimer's disease: Thinning of the RNFL and superior hemiretina. *Graefe's Archive for Clinical and Experimental Ophthalmology = Albrecht von Graefes Archiv fur klinische und experimentelle Ophthalmologie*, 255(9), 1827–1835. [PMID]
- Danesh-Meyer, H. V., Birch, H., Ku, J. Y., Carroll, S., & Gamble, G. (2006). Reduction of optic nerve fibers in patients with Alzheimer disease identified by laser imaging. *Neurology*, 67(10), 1852–1854. [PMID]

- Dentchev, T., Milam, A. H., Lee, V. M., Trojanowski, J. Q., & Dunaief, J. L. (2003). Amyloid-beta is found in drusen from some age-related macular degeneration retinas, but not in drusen from normal retinas. *Molecular Vision*, 9, 184–190. [DOI:10.1016/S0002-9394(03)00804-3] [PMID]
- Sánchez, D., Castilla-Martí, M., Rodríguez-Gómez, O., Valero, S., Piferrer, A., & Martínez, G., et al. (2014). Usefulness of peripapillary nerve fiber layer thickness assessed by optical coherence tomography as a biomarker for Alzheimer's disease. *Scientific Reports*, 8(1), 16345. [PMID] [PMCID]
- ETDRS research group investigators. Early Treatment Diabetic Retinopathy Study design and baseline patient characteristics. ETDRS report number 7(1991). *Ophthalmology*, 98(5 Suppl), 741–56. [DOI:10.1016/S0161-6420(13)38009-9]
- García-Martin, E. S., Rojas, B., Ramírez, A. I., de Hoz, R., Salazar, J. J., & Yubero, R., et al. (2014). Macular thickness as a potential biomarker of mild Alzheimer's disease. *Ophthalmology*, 121(5), 1149–1151.e3. [PMID]
- Gao, L., Liu, Y., Li, X., Bai, Q., & Liu, P. (2015). Abnormal retinal nerve fiber layer thickness and macula lutea in patients with mild cognitive impairment and Alzheimer's disease. *Archives of Gerontology and Geriatrics*, 60(1), 162–167. [PMID]
- Gharbiya, M., Trebbastoni, A., Parisi, F., Manganiello, S., Cruciani, F., & D'Antonio, F., et al. (2014). Choroidal thinning as a new finding in Alzheimer's disease: Evidence from enhanced depth imaging spectral domain optical coherence tomography. *Journal of Alzheimer's Disease: JAD*, 40(4), 907–917. [PMID]
- Grossman, I., Lutz, M. W., Crenshaw, D. G., Saunders, A. M., Burns, D. K., & Roses, A. D. (2010). Alzheimer's disease: Diagnostics, prognostics and the road to prevention. *The EPMA Journal*, 1(2), 293–303. [PMID]
- Gupta, V. K., Chitranshi, N., Gupta, V. B., Golzan, M., Dheer, Y., & Wall, R. V., et al. (2016). Amyloid beta accumulation and inner retinal degenerative changes in Alzheimer's disease transgenic mouse. *Neuroscience Letters*, 623, 52–56. [PMID]
- He, X. F., Liu, Y. T., Peng, C., Zhang, F., Zhuang, S., & Zhang, J. S. (2012). Optical coherence tomography assessed retinal nerve fiber layer thickness in patients with Alzheimer's disease: A meta analysis. *International Journal of Ophthalmology*, 5(3), 401–405. [PMID]
- Hinton, D. R., Sadun, A. A., Blanks, J. C., & Miller, C. A. (1986). Optic-nerve degeneration in Alzheimer's disease. *The New England Journal of Medicine*, 315(8), 485–487. [PMID]
- Jack, C. R., Bennett, D. A., Blennow, K., Carrillo, M. C., Dunn, B., & Haeblerlein, S. B., et al. (2018). NIA-AA Research Framework: Toward a biological definition of Alzheimer's disease. *Alzheimer's & Dementia: The Journal of The Alzheimer's Association*, 14(4), 535–562. [PMID] [PMCID]
- Koronyo-Hamaoui, M., Koronyo, Y., Ljubimov, A. V., Miller, C. A., Ko, M. K., & Black, K. L., et al. (2011). Identification of amyloid plaques in retinas from Alzheimer's patients and non-invasive in vivo optical imaging of retinal plaques in a mouse model. *NeuroImage*, 54(Suppl 1), S204–S217. [PMID] [PMCID]
- Kromer, R., Serbecic, N., Hausner, L., Froelich, L., Aboul-Enein, F., & Beutelsbacher, S. C. (2014). Detection of retinal nerve fiber layer defects in Alzheimer's disease using SD-OCT. *Frontiers in Psychiatry*, 5, 22. [PMID]
- Kwon, J. Y., Yang, J. H., Han, J. S., & Kim, D. G. (2017). Analysis of the retinal nerve fiber layer thickness in Alzheimer disease and mild cognitive impairment. *Korean Journal of Ophthalmology: KJO*, 31(6), 548–556. [PMID]
- Lad, E. M., Mukherjee, D., Stinnett, S. S., Cousins, S. W., Potter, G. G., & Burke, J. R., et al. (2018). Evaluation of inner retinal layers as biomarkers in mild cognitive impairment to moderate Alzheimer's disease. *Plos One*, 13(2), e0192646. [PMID]
- Larrosa, J. M., Garcia-Martin, E., Bambo, M. P., Pinilla, J., Polo, V., & Otin, S., et al. (2014). Potential new diagnostic tool for Alzheimer's disease using a linear discriminant function for Fourier domain optical coherence tomography. *Investigative Ophthalmology & Visual Science*, 55(5), 3043–3051. [PMID]
- London, A., Benhar, I., & Schwartz, M. (2013). The retina as a window to the brain - from eye research to CNS disorders. *Nature reviews. Neurology*, 9(1), 44–53. [PMID]
- Lu, Y., Li, Z., Zhang, X., Ming, B., Jia, J., & Wang, R., et al. (2010). Retinal nerve fiber layer structure abnormalities in early Alzheimer's disease: Evidence in optic coherence tomography. *Neuroscience Letters*, 480(1), 69–72. [PMID]
- Marziani, E., Pomati, S., Ramolfo, P., Cigada, M., Giani, A., & Mariani, C., et al. (2013). Evaluation of retinal nerve fiber layer and ganglion cell layer thickness in Alzheimer's disease using spectral-domain optical coherence tomography. *Investigative Ophthalmology & Visual Science*, 54(9), 5953–5958. [PMID]
- Moschos, M. M., Markopoulos, I., Chatziralli, I., Rouvas, A., Papageorgiou, S. G., & Ladas, I., et al. (2012). Structural and functional impairment of the retina and optic nerve in Alzheimer's disease. *Current Alzheimer Research*, 9(7), 782–788. [PMID]
- Paquet, C., Boissonnot, M., Roger, F., Dighiero, P., Gil, R., & Hugon, J. (2007). Abnormal retinal thickness in patients with mild cognitive impairment and Alzheimer's disease. *Neuroscience Letters*, 420(2), 97–99. [PMID]
- Parisi, V., Restuccia, R., Fattaposta, F., Mina, C., Bucci, M. G., & Pierelli, F. (2001). Morphological and functional retinal impairment in Alzheimer's disease patients. *Clinical Neurophysiology*, 112(10), 1860–1867. [DOI:10.1016/S1388-2457(01)00620-4]
- Polo, V., Garcia-Martin, E., Bambo, M. P., Pinilla, J., Larrosa, J. M., & Satue, M., et al. (2014). Reliability and validity of Cirrus and Spectralis optical coherence tomography for detecting retinal atrophy in Alzheimer's disease. *Eye (London, England)*, 28(6), 680–690. [PMID] [PMCID]
- Tao, R., Lu, Z., Ding, D., Fu, S., Hong, Z., & Liang, X., et al. (2019). Perifovea retinal thickness as an ophthalmic biomarker for mild cognitive impairment and early Alzheimer's disease. *Alzheimer's & Dementia (Amsterdam, Netherlands)*, 11, 405–414. [PMID] [PMCID]
- Salobarra-García, E., Hoyas, I., Leal, M., de Hoz, R., Rojas, B., & Ramírez, A. I., et al. (2014). Analysis of retinal peripapillary segmentation in early Alzheimer's disease patients. *BioMed Research International*, 2015, 636548. [PMID] [PMCID]
- Scheltens, P., Blennow, K., Breteler, M. M., de Strooper, B., Frisone, G. B., & Salloway, S., et al. (2016). Alzheimer's disease. *Lancet (London, England)*, 388(10043), 505–517. [DOI:10.1016/S0140-6736(15)01124-1]

- Srinivasan, S., & Efron, N. (2019). Optical coherence tomography in the investigation of systemic neurologic disease. *Clinical & Experimental Optometry*, 102(3), 309-319. [PMID]
- Thal, L. J., Kantarci, K., Reiman, E. M., Klunk, W. E., Weiner, M. W., & Zetterberg, H., et al. (2006). The role of biomarkers in clinical trials for Alzheimer's disease. *Alzheimer Disease and Associated Disorders*, 20(1), 6-15. [PMID]
- van de Kreeke, J. A., Nguyen, H. T., den Haan, J., Konijnenberg, E., Tomassen, J., & den Braber, A., et al. (2019). Retinal layer thickness in preclinical Alzheimer's disease. *Acta Ophthalmologica*, 97(8), 798-804. [PMID]
- Williams, P. A., Thirgood, R. A., Oliphant, H., Frizzati, A., Littlewood, E., & Votruba, M., et al. (2013). Retinal ganglion cell dendritic degeneration in a mouse model of Alzheimer's disease. *Neurobiology of Aging*, 34(7), 1799-1806. [PMID]

This Page Intentionally Left Blank